

Pituitary adenoma occurring with acromegaly coexisting with partially empty sella syndrome

Tomasz Trybek, MD, Aldona Kowalska, MD, PhD

Department of Endocrinology, Holycross Cancer Center, Kielce, Poland



Received: 02.10.2015. Accepted: 23.11.2015.

ABSTRACT

Pituitary microadenoma occurring with acromegaly coexisting with empty sella syndrome is a rare clinical case. The main symptoms result from the presence of hormonally active pituitary tumor. Empty sella syndrome may hinder correct and prompt diagnosis, which may be important for effective therapy. We present a case of a 67-year-old woman admitted to hospital with acromegaly. MRI of the pituitary revealed partially empty sella and pituitary microadenoma. The patient underwent surgery. Follow-up MRI revealed regression of the pituitary adenoma without signs of recurrence during observation. We also present a review of literature.

KEY WORDS: pituitary tumor, acromegaly, empty sella syndrome

Correspondence:

Tomasz Trybek, MD
Department of Endocrinology,
Holycross Cancer Centre, Kielce
25-734 Kielce, ul. Artwińskiego 3
tel.: (+48 41) 367-42-10
e-mail: trytom1@tlen.pl

INTRODUCTION

Empty sella syndrome results from penetration of the subarachnoid region filled with cerebrospinal fluid through the diaphragm of the sella to the sella turcica, causing compression of the pituitary gland and moving it towards the back and down. Its primary (congenital) cause stems from the inefficiency of the sellar diaphragm whereas surgery or radiation treatment of the area surrounding the pituitary as well as postpartum ischemia and spontaneous hemorrhagic infarction of pituitary adenomas may contribute to the formation of secondary empty sella syndrome. It is estimated at 5.5–23.5% in autopsy. It is usually asymptomatic and does not cause hormonal dysfunction of the pituitary gland. The confirmation of empty sella syndrome does not exclude the presence of hormone-secreting pituitary adenoma.

CASE PRESENTATION

A 67-year-old female patient with clinical symptoms of acromegaly (fig. 1, 2) was admitted to the Department of Endocrinology. She was previously treated with non-steroidal anti-inflammatory drugs because of headaches and pain due to osteoarthritis of the spine. She did not report other chronic diseases. She noticed a change in facial features and excessive sweating about 12 months ago. Physical examination showed enlargement of the distal parts of the body – hands and feet, tongue, nose, lips.

Laboratory tests have confirmed impaired glucose tolerance (fasting glucose level was 93 mg/dl and 164 mg/dl 2 hours after the oral glucose tolerance test). An ultrasound examination revealed nodular goiter with focal lesions of both lobes. The biopsy showed benign lesions in thyroid nodules. Hormone tests indicated elevated level of serum insulin-like growth factor 1 (IGF-1) (740.8 ng/ml), elevated level of human growth hormone (HGH) (5.11 ng/ml) and lack of suppression of HGH to < 0.4 ng/ml following administration of 75 g of glucose (HGH concentration was 7.64 ng/ml at the 120th minute of the test). There were no other pituitary hormonal dysfunctions. Magnetic resonance imaging (MRI) of the hypothalamic-pituitary area revealed invagination to the subarachnoid space to the sella. There was a narrow glandular tissue 4.7 mm thick on the right side and 3.5 mm thick on the left side of the sella. MRI scans revealed a heterogeneous contrast-enhanced area of 5 mm on the right side (fig. 3). The diagnosis was a pituitary microadenoma causing acromegaly coexisting with partially empty sella syndrome. The patient underwent transsphenoidal pituitary tumor resection. The treatment effect was evaluated after surgery. The level of IGF-1 was correct (52 ng/ml); however, there were elevated

FIGURE 1.

Photograph of the patient – facial features typical of acromegaly.

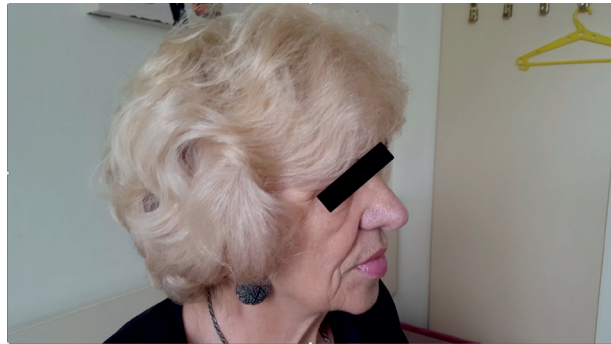
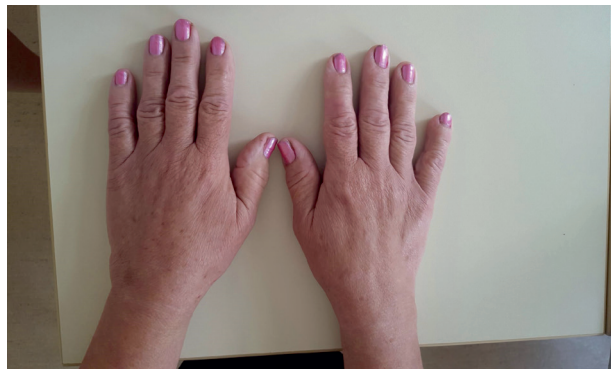
FIGURE 2.

Photograph of enlarged hands of the patient.



levels of random HGH (1.36 ng/ml) and elevated levels of HGH in the 2nd hour after the oral glucose tolerance test (0.609 ng/ml). Thus, the patient did not fulfill the criteria for cure of acromegaly, according to which the level of the random HGH should be less than 1 ng/ml or HGH less than 0.4 ng/ml in the 120th minute of the glucose test. There were no diabetes insipidus and other dysfunction of the pituitary hormone. The IGF-1 levels checked after 4 months were in the reference range and amounted to 175 ng/ml. The MRI performed after the surgery revealed the penetration of the subarachnoid space to the deepened sella and a residual glandular tissue without the presence of pituitary microadenoma (fig. 4). The patient is under observation of an endocrinologist.

DISCUSSION

Coexistence of pituitary microadenoma occurring with acromegaly and empty sella syndrome is not common. First reports about this phenomenon appeared around 1980 and most articles on this topic describe only clinical cases. In 1982, Jadresic et al. found that among 155 patients with acromegaly, 23% of them had partially empty sella syndrome [1]. In 1986, after sev-

FIGURE 3.

MRI images before surgery – pituitary microadenoma located on the right side of the sella in a patient with acromegaly coexisting with a partially empty sella.

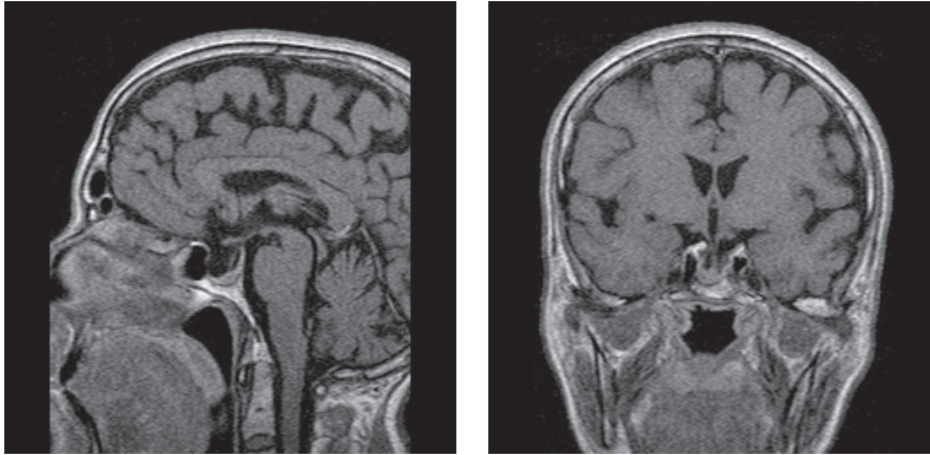
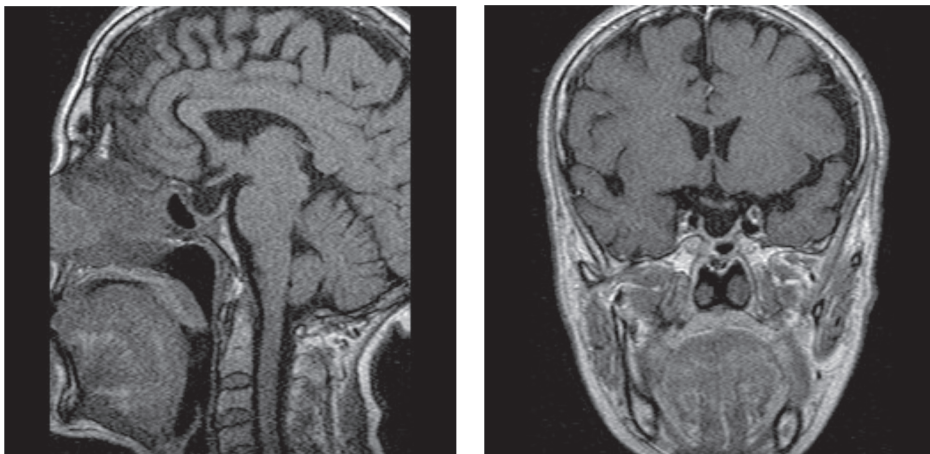


FIGURE 4.

MRI images after surgery – empty sella without microadenoma.



eral years of observation, Bjerre et al. noted that 11 patients had empty sella in a group of 23 untreated patients with acromegaly [2]. A report prepared by Chinese and Swedish authors refers to 69 patients with acromegaly and pituitary microadenomas observed in years 2004–2009. They noted 14 cases (20,3%) of empty sella syndrome among these patients. This group was compared to other patients with silent microadenomas in which empty sella syndrome was found only in 4 of them (3.9%). The authors observed a statistically significant connection between the presence of empty sella and excessive production of HGH by microadenomas ($p = 0.001$). However, this relation remains unclear and requires further study [3].

CONCLUSIONS

The diagnosis of pituitary microadenoma coexisting with empty sella syndrome may be difficult. We must remember that adenomas may also occur in suprasellar location, sphenoid sinus [4, 5], cavernous sinus and clivus [6, 7]. In these cases, the authors underline an important role of computer tomography imaging of bone structures outside the sella allowing for identification of the ectopic location of the adenoma. We always have to consider rare cases of ectopic production of growth-hormone releasing hormone (GHRH) by neuroendocrine tumors situated in lungs [8], thymus or pancreas [9]. They can secondarily cause hypertrophy of somatotrophic cells of the pituitary

gland, which results in the enlargement of the sella and the lack of adenoma in the pituitary gland.

Acknowledgements

Authors report no conflict of interest.

References

1. Jadresic A, Banks LM, Child DF et al. The acromegaly syndrome. Relation between clinical features, growth hormone values and radiological characteristics of the pituitary tumours. *Q J Med* 1982; 51: 189-204.
2. Bjerre P, Lindholm J, Videbaek H. The spontaneous course of pituitary adenomas and occurrence of an empty sella in untreated acromegaly. *Clin Endocrinol Metab* 1986; 63: 287-291.
3. Liu W, Zhou H, Neidert MC et al. Growth hormone secreting pituitary microadenomas and empty sella – an under-recognized association? *Clin Neurol Neurosurg* 2014; 126: 18-23.
4. Gondim A, Schops M, Ferreira E et al. Acromegaly due to an ectopic pituitary adenoma in the sphenoid sinus. *Acta Radiol* 2004; 45: 689-691.
5. Hori E, Akai T, Kurimoto M et al. Growth hormone-secreting pituitary adenoma confined to the sphenoid sinus associated with a normal-sized empty sella. *Clin Neurosci* 2002; 9: 196-199.
6. Coulson C, Sidcliq MA, Johnson AP. Empty sella syndrome associated with a hyperfunctioning microadenoma invading the clivus. *Neurosurg* 2007; 21: 623-625.
7. Appel G, Bergsneider M, Vinters H et al. Acromegaly due to an ectopic pituitary adenoma in the clivus case report and review of literature. *Pituitary* 2012; 15(suppl. 1): S53-56.
8. Osella G, Orlandi F, Caraci P et al. Acromegaly due to ectopic secretion of GHRH by bronchial carcinoid in a patient with empty sella. *J Endocrinol Invest* 2003; 26: 163-169.
9. Mnif Feki M, Mnif F, Charfi N et al. Ectopic secretion of GHRH by a pancreatic neuroendocrine tumor associated with an empty sella. *Ann Endocrinol (Paris)* 2011; 72: 522-525.

Authors' contributions:

Both authors equally contributed to idea & design of the article, clinical data collection, analysis and writing the manuscript.