

Case report

Myeloablative chemotherapy in testicular cancer patient

**Karolina Furgała¹, Zuzanna Smuniewska¹, Dawid Sigorski^{2,3}, Maciej Michalak^{2,4},
Lubomir Bodnar^{2,3}**

¹ Collegium Medicum, University of Warmia and Mazury

² Department of Oncology, Collegium Medicum, University of Warmia and Mazury

³ Clinical Department of Oncology and Immuno-Oncology, Warmian-Masurian Cancer Center of The Ministry of The Interior and Administration's Hospital, Olsztyn, Poland

⁴ Department of Radiology, Warmian-Masurian Cancer Center of The Ministry of The Interior and Administration's Hospital, Olsztyn, Poland

Correspondence:

Zuzanna Smuniewska
Collegium Medicum,
University of Warmia and Mazury
10-082 Olsztyn, Poland, al. Warszawska 30
e-mail: zuzanna.smuniewska@
student.uwm.edu.pl

Received:

13.01.2021

Accepted:

03.03.2021

DOI: 10.24292/01.OR.121030321

Copyright © Medical Education.

All rights reserved.

ABSTRACT

Chemotherapy is the standard treatment for metastatic testicular cancers. The autologous hematopoietic stem cell transplantation is a salvage option for relapsed patients. The paper presents a case of a 20-year-old patient with stage IIIC non-seminoma treated with BEP chemotherapy and autologous transplantation of stem cells, which allowed to achieve durable remission.

Key words: chemotherapy, autologous hematopoietic stem cell transplantation, non-seminoma

CASE REPORT

A 20-year-old patient with a testicular tumour was admitted to the Urology Department in April 2019. He had been experiencing abdominal pain since January 2019 and testicular pain since March 2019. He had lost 12 kg in the last 3 months before admission. Physical examination revealed cachexia, enlarged left supraclavicular lymph nodes, palpable liver 15 cm below the right costal arch and testicular tumour. His initial performance status according ECOG scale was 3: capable of only limited selfcare, confined to bed or chair more than 50% walking hours. A left-sided orchidectomy was performed and embryonal carcinoma (85%) and teratoma (15%) were diagnosed. Computed tomography (CT) revealed metastases to the left kidney and adrenal glands, as well as numerous metastases to the liver, lungs and lymph nodes (fig. 1). The initial test results are shown in the table 1.

FIGURE 1.

Pre-treatment abdominopelvic CT scan revealed numerous poorly vascularized metastatic lesions to the liver and massive retroperitoneal lymphadenopathy.

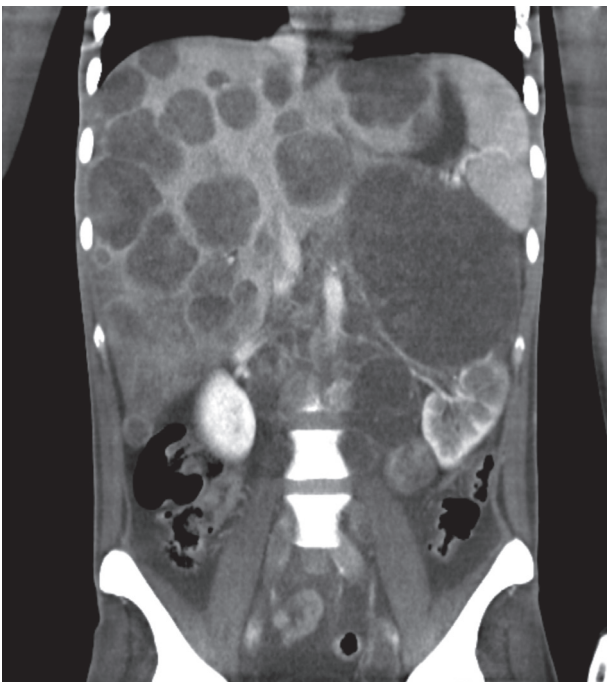


TABLE 1.

The patient's laboratory test results at the start of treatment.

Indicator	The patient's values	Normal
RBC ($10^6/\mu\text{l}$)	4.49	4.63–6.08
Hematocrit (%)	35.5	41–51
Hemoglobin (g/dl)	10.7	13.5–18
Alanine aminotransferase (U/l)	212	2–41
Aspartate aminotransferase (U/l)	493	2–40
Bilirubin (mg%)	1.94	0.00–1.20
Uric acid (mg%)	8.9	3.4–7.0
Potassium (mEq/l)	6.3	3.5–5.1
C-reactive protein (mg/l)	202.45	< 5

The patient was admitted to the Oncology Department in May 2019. Non-seminoma testicular cancer (pT2 cN1 cM1b, S3) was diagnosed in stage IIIC, with unfavourable prognosis. The patient required extensive supportive care (prophylaxis of tumour lysis syndrome, parenteral nutrition, prophylactic antibiotic therapy, and granulocyte colony-stimulating factor). The patient was qualified for four cycles of the bleomycin, etoposide and cisplatin (BEP) chemotherapy regimen. The first course of chemotherapy was complicated by pancytopenia requiring blood transfusion and septic shock with *Enterococcus faecium* (VRE) infection. The tolerance to the next three cycles was moderate. CT examination and lab tests performed after four cycles of BEP chemotherapy in August 2019 showed a 33% reduction in metastatic masses according to RECIST 1.1 criteria, without normalization of tumour markers (tab. 2). The patient was qualified for high-dose consolidation chemotherapy after conventional chemotherapy with autologous hematopoietic stem cell transplantation (auto-HSCT). The auto-HSCT procedure included paclitaxel and ifosfamide chemotherapy, mobilization and separation of stem cells, myeloablative chemotherapy with carboplatin and etoposide (the dose of chemotherapy was reduced to 50% due to performance status) and CD34⁺ cell transfusion (May 2020). After the transplant procedure, PET examination revealed no changes, with increased metabolism of 18F-FDG. The patient remains under observation with no signs of relapse (fig. 2). Tumour markers remain within normal ranges (December 2020) (tab. 2).

FIGURE 2.
Follow-up CT scan. Post-treatment disappearance of liver metastases. Partial regression of metastatic lymph nodes with dystrophic calcifications.

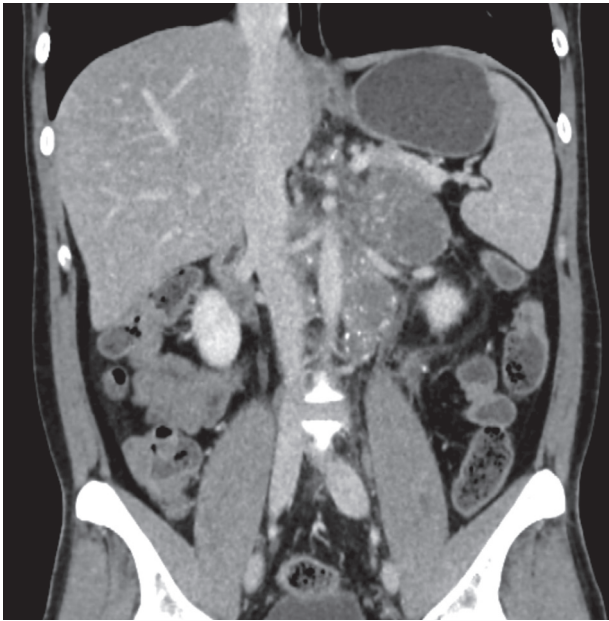

TABLE 2.
The patient's laboratory test results of tumor markers.

	May 2019	August 2019	December 2020	Normal
AFP (IU/ml)	31 691	23.090	2.830	0.000–5.800
HCG β (mIU/ml)	75 849	4.630	< 0.100	< 0.100
LDH (U/l)	15 259	424	258	240–480

References

1. Mead GM, Stenning SP; Clinical Oncology Editorial. The International Germ Cell Consensus Classification: A New Prognostic Factor-Based Staging Classification for Metastatic Germ Cell Tumours. *Clin Oncol (R Coll Radiol)*. 1997; 9(4): 207-9.
2. Einhorn LH, Williams SD, Chamness A et al. High-dose chemotherapy and stem-cell rescue for metastatic germ-cell tumors. *N Engl J Med*. 2007; 357: 340-8.
3. McHugh DJ, Feldman DR. Conventional-dose versus high-dose chemotherapy for relapsed germ cell tumors. *Adv Urol*. 2018; 2018:7272541.
4. Lorch A, Bascoul-Mollevis C, Kramar A et al. Conventional-dose versus high-dose chemotherapy as first salvage treatment in male patients with metastatic germ cell tumors: evidence from a large international database. *J Clin Oncol*. 2011; 29: 2178-84.
5. Feldman DR, Sheinfeld J, Bajorin DF et al. TI-CE high-dose chemotherapy for patients with previously treated germ cell tumors: results and prognostic factor analysis. *J Clin Oncol*. 2010; 28: 1706-13.

Authors' contributions:

All authors contributed to the study conception and design. Idea for the article, literature search and data analysis were performed by Zuzanna Smuniewska, Karolina Furgała, Maciej Michalak. The first draft of the manuscript was written by Zuzanna Smuniewska, Karolina Furgała and all authors commented on previous versions of the manuscript. Dawid Sigorski and Lubomir Bodnar critically revised the work. All authors read and approved the final manuscript.

Conflict of interests:

Authors declare no conflict of interest.

Financial support:

There was no financial support.

Ethics:

The authors had full access to the data and take full responsibility for its integrity.

All authors have read and agreed with the content of the manuscript as written.

The paper complies with the Helsinki Declaration, EU Directives and harmonized requirements for biomedical journals.

DISCUSSION

According to the criteria of the International Germ Cell Cancer Collaborative Group, the patient was initially classified as having a poor prognosis [1]. The BEP chemotherapy regimen remains the standard I line treatment option for patients with stage III non-seminoma tumours. In patients who have partially responded to standard treatment, the salvage therapy is needed. Due to inconsistencies between data comparing two strategies and the rarity of the patient population, a universally recommended approach in the initial salvage setting is lacking. There are mainly two strategies: conventional-dose chemotherapy (CDCT), mostly in VeIP, TIP or GIP regimen or HDCT with auto-HSCT. There are no studies that clearly demonstrate the advantage of one option [2, 3]. There are data that in high risk group of patients is advantage of HDCT over CDCT in terms on progression-free survival and overall survival [3, 4].

CONCLUSIONS

According to the data, in the absence of safety concerns, HDCT should not be excluded in patients from any risk group [5]. Despite the advances in oncology, testicular cancer therapy is still based on classical cytostatics. Understanding the biology of testicular cancer and developing new therapeutic options is an urgent need in the group of patients resistant to chemotherapy.