



## CASUISTIC PAPER

Anna Pliszka <sup>1(ABCDEFGH)</sup>, Michał Kłos <sup>2(ABCDEFGH)</sup>, Klaudia Możdżeń <sup>1(ABCDEFGH)</sup>,  
Krzysztof Balawender <sup>3,4(ABCDEFGH)</sup>

# Urolithiasis due to renal dystopia and vascular anomalies

<sup>1</sup> Student's Anatomical Scientific Club, Institute of Medical Sciences, Medical College of Rzeszow University, Rzeszow, Poland

<sup>2</sup> Municipal Hospital in Siemianowice Slaskie, Siemianowice Slaskie, Poland

<sup>3</sup> Department of Urology and Urological Oncology, Municipal Hospital in Rzeszow, Rzeszow, Poland

<sup>4</sup> Department of Morphological Sciences, Institute of Medical Sciences, Medical College of Rzeszow University, Rzeszow, Poland

## ABSTRACT

**Introduction.** Variations in the urogenital vascular anomalies in the abdomen are common. However, they warrant attention due to their importance in operative, diagnostic, and endovascular procedures.

**Aim.** The aim of this article is to show an example of a patient with rare kidney and vessels anomalies. We want to prove that those anomalies contributed to development of urolithiasis in this case.

**Description of the case.** During dissection of abdomen in a female cadaver, unique vascular anomalies and a position disorder of both kidneys were observed.

**Conclusion.** Vessel abnormalities were congenital and appeared simultaneously with renal dystopia. Both anomalies could contribute to stone formation and nephritis. Understanding of the urogenital anatomical variations and their relations to adjacent structures is significant during surgical and radiological procedures.

**Keywords.** renal anomalies, urolithiasis, vascular anomalies

## Introduction

Congenital abnormalities of kidney and urinary tract occur in 3.3%-11.1% of the population.<sup>1</sup> Renal malrotation is a rare congenital variation of kidneys and hilum position, more common in males, with a prevalence of 1 in 2000 autopsies. The process of nephrogenesis is important to understand since most developmental abnormalities arise during the period of nephron formation. The sensitive exposure window, consisting of prenatal

or postnatal periods of structural and functional development of the kidney, during which chemical agents or trauma may lead to kidney damage.<sup>2</sup> Congenital anomalies of kidney and urinary tract occur approximately 20,7 per 10 000 births according to the Polish Registration of Congenital Anomalies.<sup>3</sup>

Renal dystopia is a position disorder of the one or both kidneys, which is associated with disturbances in the process of their ascending, in other words they do

**Corresponding author:** Krzysztof Balawender, e-mail: balawender82@gmail.com

**Participation of co-authors:** A – Author of the concept and objectives of paper; B – collection of data; C – implementation of research; D – elaborate, analysis and interpretation of data; E – statistical analysis; F – preparation of a manuscript; G – working out the literature; H – obtaining funds

Received: 28.09.2020 | Accepted: 1.12.2020

Publication date: March 2021

not reach their target location. One-sided dislocation is the inhibition of the kidney through its natural path of ascending. Cross displacement is a change in the direction of ascend. The kidney is then situated in an abnormal position outside its natural ascending path.<sup>4</sup> Displaced kidneys are more frequently located on the left side (80% of cases), characterized as hypoplastic and have an imperfect turn. The length of renal vessels and ureters are appropriate to the location of kidneys.<sup>5</sup>

Urolithiasis is a multiple and intersectional disease which results from multiple interactions between geographical, climatic, ethnic and genetic factors. The development of urolithiasis can be also induced by lifestyle factors such as eating habits or decreased intake of fluid. Hormonal or anatomical abnormalities also influence its pathogenesis.<sup>6,7,8</sup>

### Aim

The aim of this article is to show an example of a patient with rare kidney and vessels anomalies. We want to prove that those anomalies contributed to development of urolithiasis in this case.

### Description of the case

Presented case showing rare kidney and vascular anomalies was found in corpse of the prosectoring collection of the Department of Human Anatomy University of Rzeszow during dissection of 64 years old women. Unfortunately, we were not be able to obtain more information about the history of hospitalization and death of that woman.

### Renal dystopia in patient

The observed position of the kidneys indicates a developmental defect - malrotation during normal fetal development, the kidneys migration from the sacral to the lumbar region, caused by the growth of the posterior abdominal wall is followed by rotation. In this case, the kidneys did not rotate properly by 90 degrees, hence their hila point upwards, not medially.

### Morphological changes in the left kidney

Smaller than the right one, with following dimensions - longitudinal dimension: 7 cm, transverse dimension: 3 cm, sagittal dimension: 3.5 cm. The thickness of the parenchyma was smaller than on the right side. We observed dilatation of pyelocalyceal system and abnormal arrangement of vessels in the hilum (extra renal arteries running in front, artery bifurcating in front of the hilum between the pelvis) (Fig 1-3). Comparing to correct and most common variant, the left kidney has a greater longitudinal dimension than the right, it is slightly thicker and lies higher than the right one.

The left ureter run between two branches of the renal artery in the hilum, then descended downwards cov-

ered with colonic vessels, on the psoas major muscle, lied laterally from the common iliac vessels, without crossing them. Moreover, the left colon artery run directly on the left ureter, which is laterally displaced from the correct position, and which may have caused additional compression and impeded the urine flow even more (Fig 2). During the widened ureter opening we found a stone. After the kidney was cut transversely and dilated, we saw multiple stones as well.



**Fig. 1.** Arteries anomaly, *Courtesy of Chair of Anatomy*  
1 – right renal artery, 2 – left renal artery, 3 – right common iliac vein, 4 – left ureter, 5 – left common iliac vein, 6 – left renal vein, l – inferior vena cava

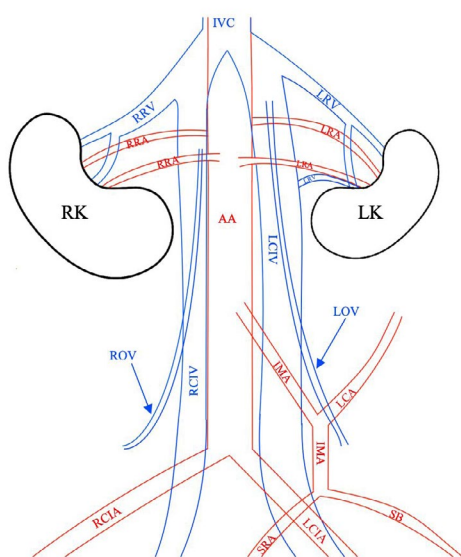


**Fig. 2.** Veins anomaly, *Courtesy of Chair of Anatomy*  
1 – vena cava inferior, 2 – right renal vein branch, 3 – right renal vein branch, 4 – right common iliac vein, 5 – left renal vein branch, 6 – left renal vein branch, 7 – left common iliac vein; yellow arrows – ureters (the left – significantly widened along its entire length)

### Morphological changes in the right kidney

Bigger than the left one, with dimensions - longitudinal dimension: 8 cm, transverse dimension: 6 cm, sagit-

tal dimension: 4.5 cm. The thickness of the parenchyma was greater than that of the left kidney uneven, lumpy and rough surface indicated chronic inflammation. We noticed also abnormal arrangement of the vessels in the hilum (an extra renal artery that runs to the lower pole of the kidney) (Fig 1-3). Enlargement of the size, greater thickness of the parenchyma and the ureter with a lumen of the correct diameter may indicate that the kidney has compensatively grown and has partially taken over function of the left kidney. Course of the right ureter is placed normally, it exited the kidney cavity rearward from the vein and artery, then run on the psoas major muscle, forward from the common iliac vessels.



**Fig. 3.** Diagram of vessel anomaly (picture does not reveal correct proportions; some irrelevant vessels were omitted; author: Anna Pliszka)

RK – right kidney, LK – left kidney, AA – abdominal aorta, RRA – right renal artery, LRA – left renal artery, IMA – inferior mesenteric artery, LCA – left colic artery, SB – sigmoid branches, SRA – superior rectal artery, RCIA – right common iliac artery, LCIA – left common iliac artery, IVC – inferior vena cava, RRV – right renal vein, LRV – left renal vein, RCIV – right common iliac vein, LCIV – left common iliac vein, ROV – right ovarian vein, LOV – left ovarian vein

### Vascular anomalies

We found additional renal arteries and veins, high joint of common iliac veins, and longer common iliac arteries (Fig. 1-2). The kidney was primarily vascularized by the branches of the common iliac artery when entering the lumbar region, it obtained vascularization from the abdominal aorta, while the branches originating from the common iliac artery disappeared.<sup>9</sup> Each kidney has an additional renal artery that extends from the abdominal aorta. We also observed long common iliac veins

(the right common iliac vein is 20 cm long, while the left – 28 cm) joined into a short inferior vena cava above the renal arteries (at the level of the first lumbar vertebra L1). The left renal vein entered the left common iliac vein. The dissection also showed that the renal veins entered the inferior vena cava at an acute angle, so they do not form a typical „cross pattern”. When it comes to longer common iliac arteries in this case –the length of the right and left arteries is 10 cm (to compare, the average length of the common iliac arteries is 5 cm).<sup>10</sup> Survived and accessory vessels pressed on the ureter and impeded the flow of urine from the kidney pelvis.

### Discussion

The renal anatomy and its development are complex. This complexity is associated with numerous variations. Each renal variation has its own clinical and surgical importance

Frequently, malrotation of the kidney with vascular aberrations predisposes patients to renal or ureteral obstruction, with consequent upper tract infections, stone formation, and abdominal pain; other common symptoms are hypertension and renal disorders, or even kidney failure. Urine in some cases may flow backward from the bladder to the kidney, leading to vesicoureteral reflux and kidney scarring.

Although renal dystopia is not the most common anomaly to deal with, urologists and surgeons should be aware of its sometimes even unexpected occurrence during their practice. More frequent pathology is horseshoe kidney (incidence of renal stones about 20% – 40%) and ectopic kidney – ectopic pelvic, crossed ectopic fused or separate (about 37% has insignificant residual fragments while normal kidneys – 18,5%).<sup>11,12</sup> Such cases need special approach in treatment. According to the algorithm the management depends on the stone(s) size, density in Hounsfield Units (HU), occurrence and type of vessels anomalies, kidneys number and location and urinary tract drainage. The final surgical procedures are percutaneous nephrolithotomy (PCNL), retrograde intrarenal surgery (RIRS), extracorporeal shock wave lithotripsy (ESWL), laparoscopic pyelolithotomy (LP).<sup>11</sup>

More complicated cases might need more modern procedures using robots such as robotic pyelolithotomy.<sup>13</sup> We have to be aware of possibility of rare kidney anomalies occurrence such as kidney malformations in our practice and detect them to provide complications during surgery and other following diseases. There are modern and precise procedures which we should use in such rare and complicated cases to decrease the risk of complications related to abnormal kidney location or vessel anomalies.

Kidneys rotation and vessel formation occur in the same time during embryological development.<sup>14,15</sup> Vessel abnormalities were congenital and appeared simulta-

neously with renal dystopia. Concluding, both anomalies contribute to kidney or ureteral obstruction, with consequent upper tract infections, stone formation and nephritis.<sup>16-18</sup> Abnormal position of kidneys and abdominal vessel anomalies represent indirectly a risk factor for urinary tract diseases. The diseases are recurrent urinary tract infections and secondary development of urolithiasis due to the abnormal passage of the upper urinary tract.<sup>11,19,20</sup>

## Conclusion

The nephrolithiasis could appear due to incorrect position of the kidney associated with presence of additional blood vessels impeding urine flow to the bladder and caused urine retention in renal pelvis. This process not only contributed to upper urinary tract distension, but also to the formation of stones. Uneven, rough surface, size enlargement and parenchyma thickening are obvious post-mortem evidence that patient underwent nephritis; we can conclude that it was caused by nephrolithiasis due to the dystopia.

On second thought, vascular anomalies could simultaneously be a risk factor for urolithiasis. The abnormally located vessels pressed on the ureter and led to urine flow perturbation. That process caused urine retention, which leads to urolithiasis. Moreover, in that variant of the disease's etiology, retention should have been also in renal pelvis so that fact explains its distension, kidney stones and nephritis.

## References

- McMahon AP. Development of the Mammalian Kidney. *Curr Top Dev Biol.* 2016; 117: 31-64.
- Seely JC. A brief review of kidney development, maturation, developmental abnormalities, and drug toxicity: juvenile animal relevancy. *J Toxicol Pathol.* 2017;30(2):125-133.
- Latos-Bielenska A, Materna-Kirylyuk A. *Wrodzone wady rozwojowe w Polsce w latach 2005-2006. Dane z Polskiego Rejestru Wrodzonych Wad Rozwojowych.* Poznań: Wydawnictwo Naukowe Uniwersytetu Medycznego im. Karola Marcinkowskiego w Poznaniu, 2010:16-17.
- Muttarak M, Sriburi T. Congenital renal anomalies detected in adulthood. *Biomed Imaging Interv J.* 2012;8(1):e7.
- Lewicki A, Jakubowski W. Diagnostyka ultrasonograficzna wad wrodzonych nerek. *Przegląd urologiczny.* 2015;3:5-13.
- Yasui, T, Okada A, Hamamoto S, et. al. Pathophysiology-based treatment of urolithiasis. *Int J Urol.* 2017;24:32-38.
- Gallucci M, Vincenzoni A, Schettini M, Fortunato P, Casanelli A, Zaccara A. Extracorporeal Shock Wave Lithotripsy in Ureteral and Kidney Malformations. *Urologia internationalis.* 2001;66:61-65.
- Rana AM, Bhojwani JP. Percutaneous nephrolithotomy in renal anomalies of fusion, ectopia, rotation, hypoplasia, and pelvicalyceal aberration: uniformity in heterogeneity. *J Endourol.* 2009;23(4):609-614.
- Zăhoi DE, Miclăuș G, Alexa A, et al. Ectopic kidney with malrotation and bilateral multiple arteries diagnosed using CT angiography. *Rom J Morphol Embryol.* 2010;51(3):589-592.
- Cocheteux B, Mounier-Vehier C, Gaxotte V, McFadden EP, Francke JP, Beregi JP. Rare variations in renal anatomy and blood supply: CT appearances and embryological background. A pictorial essay. *Eur Radiol.* 2001;11(5):779-786.
- Singh AG, Jairath A, Balaji SS, et. al. Changing trends in the endourological management of urolithiasis in anomalous kidneys. *BJU Int.* 2019;123:318-327.
- Wang C, Jin L, Zhao X, Li G, Xue B. Minimally invasive treatment of an ectopic kidney stone: a case report and literature review. *J Int Med Res.* 2019;47(9):4544-4550.
- Al-Yousef R, Almarzouq A, Aldousari S. Robotic pyelolithotomy in a congenital pelvic kidney: side docking and robotic prostatectomy port - site approach. *Int Braz J Urol.* 2017;43(2):374.
- Upadhyay KK, Silverstein DM. Renal development: a complex process dependent on inductive interaction. *Curr Pediatr Rev.* 2014;10(2):107-114.
- Renal System Development. UNSW Embryology. [https://embryology.med.unsw.edu.au/embryology/index.php/Renal\\_System\\_Development](https://embryology.med.unsw.edu.au/embryology/index.php/Renal_System_Development). Published 24 September 2020.
- Di Giuliano F, Picchi E, Lacchè A, et al. Congenital kidney malformation: Computed tomography and scintigraphy findings of renal reversed rotation. *Radiol Case Rep.* 2019;14(6):678-682.
- García-Perdomo HA, Solarte PB, España PP. Pathophysiology associated with forming urinary stones. *Urol Colomb.* 2016;25:118-125.
- Natami M, Makarem A, Ahmed F, Dastgheib N, Zahraei, AH. A giant ureteral stone in a 32-year-old man: a case report. *Int Med Case Rep J.* 2019;12:43-46.
- Peres LA, Ferreira JR, Beppu AP, de Araújo Junior ER, Vicenzi G, Yamamoto RY. Anatomical alterations in patients with nephrolithiasis. *J Bras Nefrol.* 2010;32(1):33-36.
- Cinman N, Okeke Z, Smith A. Pelvic Kidney: Associated Diseases and Treatment. *J Endourol.* 2007;21:836-842.