

# Auditory ossicles in Scanning Electron Microscopy

## Authors' Contribution:

A – Study Design

B – Data Collection

C – Statistical Analysis

D – Data Interpretation

E – Manuscript Preparation

F – Literature Search

G – Funds Collection

Agnieszka Wiatr<sup>ABCDE</sup>, Jacek Składzień<sup>BDF</sup>, Maciej Wiatr<sup>ABGE</sup>

Faculty of Medicine, Jagiellonian University Collegium Medicum, Poland; Head: prof. Jacek Składzień MD PhD

Article history: Received: 26.04.2020 Accepted: 12.05.2020 Published: 13.05.2020

## ABSTRACT:

**Introduction:** Knowledge about the physiology of a healthy middle ear is essential for understanding the activity and mechanics of the ear as well as the basics of ossiculoplasty. Trauma of the epithelial lining of the tympanic cavity as well as the ossicular chain may be the result of chronic inflammation and surgery. Depending on the observed changes of the middle ear lining, there are several types of distinguished chronic inflammatory changes: simple, with cholesteatoma, with the formation of inflammatory granulation tissue, in course of specific diseases.

**Purpose:** The aim of the article is presentation of the microstructure and vasculature of the ossicular chain in the Scanning Electron Microscope. Particular attention is drawn to the anatomical aspects of the structure and connections of auditory ossicles as vital elements for reconstruction of the conduction system of the middle ear.

**Material and method:** The analysis covered auditory ossicles standardly removed in accordance with the methodology of the investigated surgical procedures. The preparations were evaluated in a scanning electron microscope.

**Results:** The exposure of bone surface promotes deep erosion. The advanced process of destruction of bone surface in the case of chronic otitis media correlates with a significant degree of damage to both the lining covering the auditory ossicles and that surrounding articular surfaces.

**Conclusions:** (1) The ossicles in the image of the Scanning Electron Microscope are covered with lining. It passes from the surface of the ossicles to the vascular bundles, forming vascular sheaths; (2) Damage to lining continuity on the surface of the auditory ossicles promotes the rapid destruction of bone tissue in the inflammatory process; (3) The dimensions of the individual ossicles are respectively: malleus – 8.36 +/- 0.01, incus – 8.14 +/- 0.0, stapes – 3.23 +/- 0.01 mm. Behavior of the anatomical length of ossicular chain during tympanoplasty appears to be essential to maintaining adequate vibration amplitude of the conductive system of the middle ear.

## KEYWORDS:

middle ear surgery, ossicular chain, Scanning Electron Microscope

## ABBREVIATIONS

CNS – central nervous system

## INTRODUCTION

The ear is divided into three parts: the outer, middle and inner ear. The middle ear consists of: the tympanic cavity with a chain of auditory ossicles, the mastoid cavity with the pneumatic system of the temporal bone and the Eustachian tube. Mammals have three auditory ossicles; in addition to the phylogenetically older stapes, those are: a malleus derived from an articular bone and an incus, which is a homologue of the square bone in reptiles. The auditory ossicles, described in 1543 by Vesalius, and again in 1546 by Ingrassia, show low metabolic activity throughout the entire human life (without resorption and renewal processes). Unlike all other bones, they are covered with lining, and not an osteogenic layer. Histologically, this lining is neither the periosteum nor mucosa, while it is similar to the latter in structure. The auditory ossicles are connected with each other by means of joints, and

with the walls of the tympanic cavity via ligaments. The malleus is fused partly with the tympanic membrane, the incus is connected by a stem with the malleus head (incudomalleal joint), and the long mastoid with the head of the stapes (incudostapedial joint). The base of stapes closes the oval window through the annular ligament. Vascularization of the tympanic cavity is very rich and stems from: the anterior, posterior, lower and upper tympanic arteries, as well as from the caroticotympanic branch, stapedia branch, mastoid branches and petrosquamous branches. The veins accompany the arteries. Venous outflow from the middle ear leads to the pterygoid plexus, the central meningeal veins, the inferior petrosal sinus and the jugular bulb. All elements and connections in the ossicular chain affect its mobility and the efficiency of sound conduction, i.e. the transmission of energy of sound waves from the external environment to the receptor elements. Knowledge of proper middle ear physiology is essential for understanding ear function and mechanics, as well as the basics of tympanoplasty. The preservation of physiological mechanisms of sound transmission in the ossicular chain and tympanic membrane system during cofosurgery allows to achieve good postoperative results in terms of hearing improvement [1–4].

**Tab. I.** Characteristics of analyzed group.

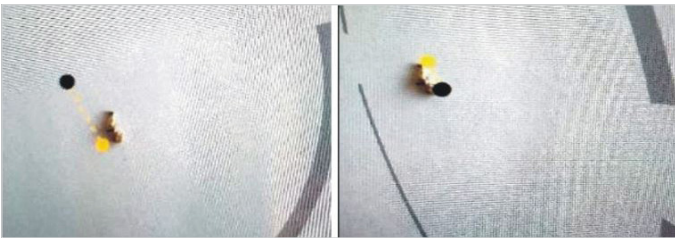
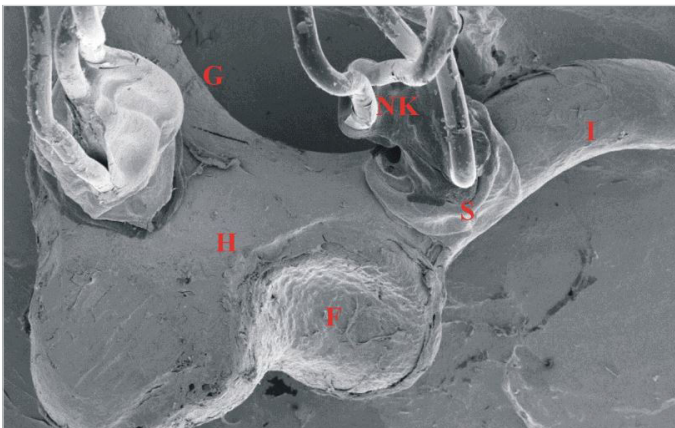
PATIENT NUMBER	AGE (YEARS)	GENDER	DIAGNOSIS	POSTOPERATIVE MATERIAL
P1	34	F	stapedectomy	stapes
P2	57	F	ossiculoplasty	incus
P3	44	M	ossiculoplasty	meatus, incus
P4	41	F	stapedectomy	stapes
P5	65	F	radical surgery	meatus, incus
P6	37	F	stapedectomy	stapes
P7	43	M	ossiculoplasty	incus
P8	67	M	radical surgery	meatus, incus
P9	54	M	radical surgery	meatus, incus
P10	52	F	stapedectomy	stapes

F – female, M – male, P – patient

**Tab. II.** Dimensions of ossicles.

OSSICLE/DIMENSION (AVERAGE FROM MEASUREMENT)	MM
Meatus	Length 8.36 +/- 0.01
Incus	Length 8.14 +/- 0.01
Stapes	Length 3.23 +/- 0.01

mm – millimeter

**Fig. 1.** Laser measurement of auditory ossicles.**Fig. 2.** Incus, 20x magnification (Scanning Microscopy Laboratory CM UJ K. Świeży). G – the short crus of incus, H – body of incus, I – the long crus of incus, F – incudomalleal joint, NK – blood vessels, S – mucosa.

## PURPOSE

The aim of the article is presentation of the microstructure and vasculature of the ossicular chain using the Scanning Electron

Microscope. Particular attention was drawn to aspects of the structure and connections of the ossicular chain as substantial elements underlying the principles of reconstruction of the conduction system of middle ear.

## MATERIAL AND METHOD

The analysis covered auditory ossicles normally removed according to the methodology of the investigated surgical procedures (stapedotomy, stapedectomy, radical surgery, tympanoplasty). In each case, participation in trials did not affect: the performed medical procedure, conduct and the outcome of medicinal approach.

Consent for the above procedure was obtained from the Bioethics Commission under number 1072.6120.2.2017 of 18 May 2017; patient consent was obtained as well.

The analysis also included 10 patients (Tab. I.).

The auditory ossicles were measured for the longest dimensions of the malleus, incus and stapes.

Auditory ossicles were prepared by fixing in 4% formalin for evaluation using scanning microscope. This was followed by dehydration of preparations in a series of ethyl alcohols with increasing concentrations: 35%, 50%, 75%, 96%, 99,9%. The prepared samples were air dried and glued to plates using adhesive (Electrodag 915 Silver Paint from TAAB). Such preparations were sprayed with a thin layer of gold using a JEOL JEE-4x (Vacuum Evaporator) device, and evaluated in a scanning electron microscope.

Data obtained during the research work were submitted to a statistical analysis. The first trial was Fisher's exact test, also referred to in the literature as the analysis of variance. Its function is to study the impact of a classifying factor on the results of a study. In the work, the null hypothesis means that the average values of given parameters are statistically equal. The alternative hypothesis is an inverse statement representing that the means are not equal. Statistical testing using the analysis of variance consisted in determining the F0 function. The null hypothesis  $H_0$ , indicating that all means are equal, was rejected with the risk of error  $\alpha$  when  $F_0 > \alpha FN-kk-1$  [5].

## RESULTS

Laser measurement of the auditory ossicles allowed to obtain average values, which are presented in Tab. II. (Fig. 1., Tab. II.).

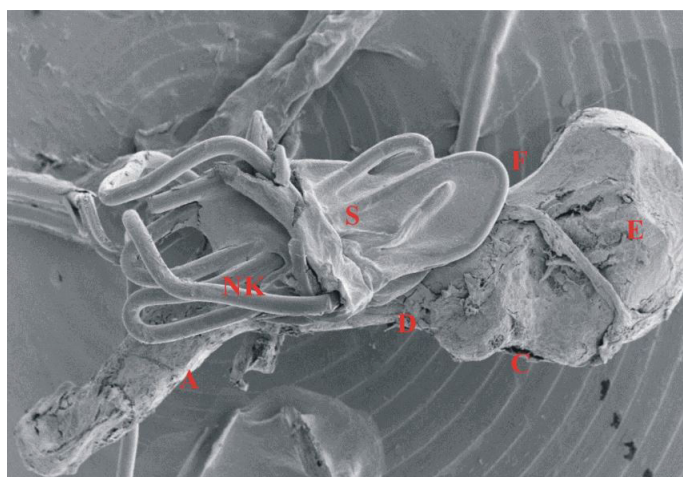
The Scanning Electron Microscope allowed to obtain images shown in Figs. 2.–12.

The results of ossicular auditory observation in the Scanning Electron Microscope are presented in Tab. III.

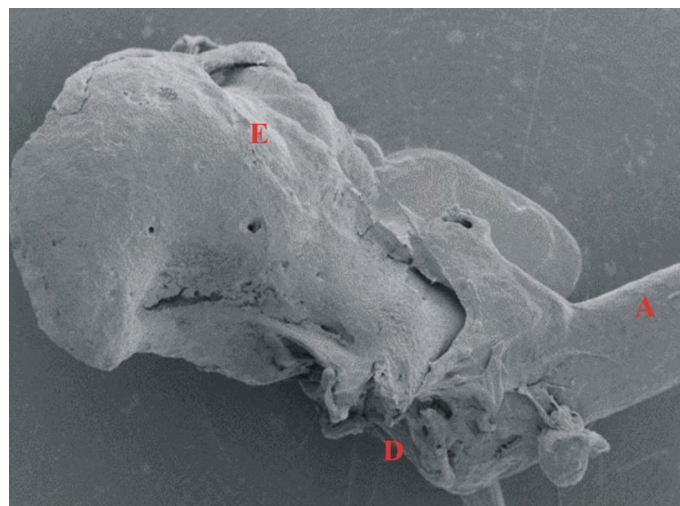
In each case, evaluation of the preparations in the Scanning Electron Microscope revealed damage to the lining covering the

**Tab. III.** Observation results from the Electronic Electron Microscope of the auditory ossicles.

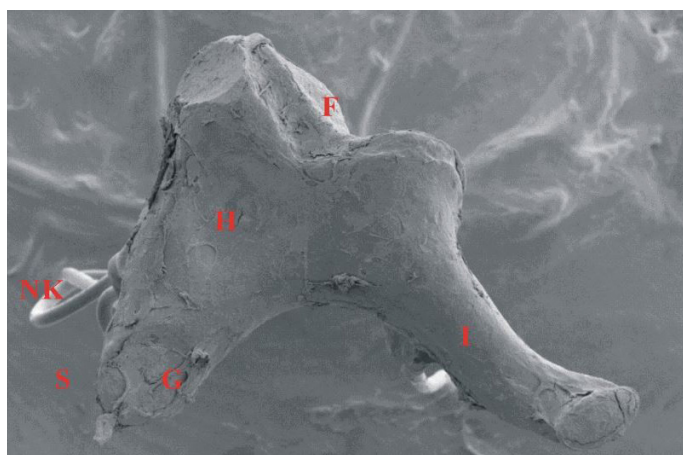
PATIENT NUMBER	CONDITION OF MUCOSA IN SEM	CURRENT VASCULARIZATION IN SEM	CONDITION OF BONE SURFACE IN SEM	DIAGNOSIS	POSTOPERATIVE MATERIAL
P1	damaged	no	no bone erosion	<i>stapedectomy</i>	stapes
P2	damaged	preserved	superficial damage	ossiculoplasty	incus
P3	damaged	preserved	deep erosion	ossiculoplasty	meatus, incus
P4	damaged	no	no bone erosion	<i>stapedectomy</i>	stapes
P5	damaged	no	deep erosion	radical surgery	meatus, incus
P6	damaged	no	no bone erosion	<i>stapedectomy</i>	stapes
P7	damaged	preserved	deep erosion	ossiculoplasty	incus
P8	damaged	preserved	deep erosion	radical surgery	meatus, incus
P9	damaged	no	deep erosion	radical surgery	meatus, incus
P10	damaged	no	no bone erosion	<i>stapedectomy</i>	stapes



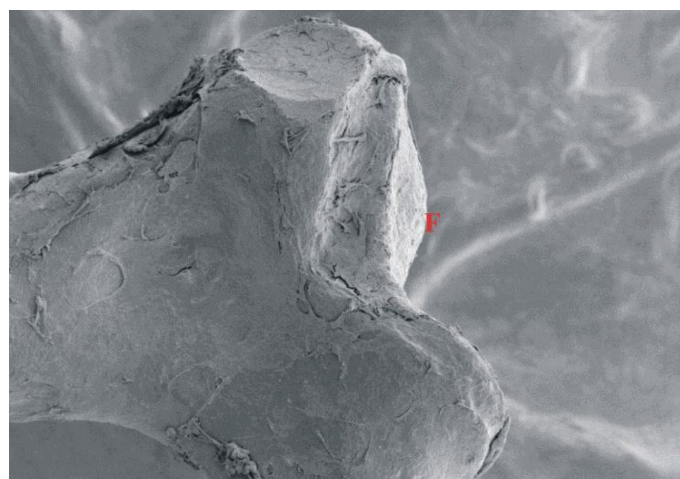
**Fig. 3.** Meatus, 15x magnification (Scanning Microscopy Laboratory CM UJ K. Świeży). A – handle of malleus, C – lateral process, D – neck of malleus, E – head of malleus, F – incudomalleal joint, NK – blood vessels, S – mucosa.



**Fig. 4.** Meatus, 30x magnification (Scanning Microscopy Laboratory CM UJ K. Świeży). A – handle of malleus, D – neck of malleus, E – head of malleus.



**Fig. 5.** Incus, 13x magnification (Scanning Microscopy Laboratory CM UJ K. Świeży). F – incudomalleal joint, G – the short crus of incus, H – body of incus, I – the long crus of incus, NK – blood vessels, S – mucosa.

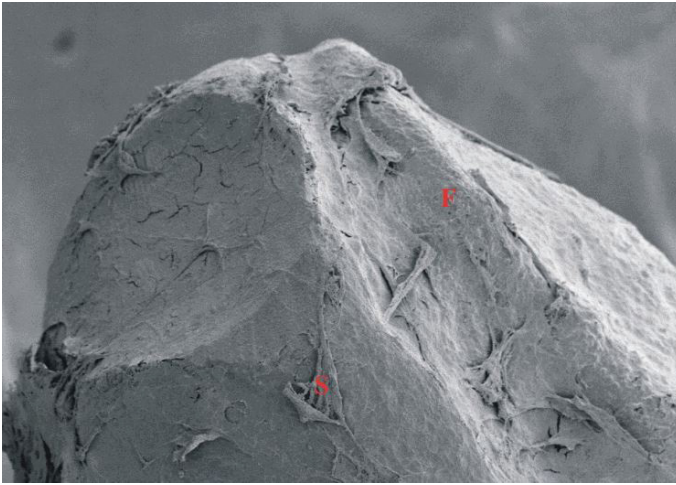


**Fig. 6.** Kincus, 24x magnification (Scanning Microscopy Laboratory CM UJ K. Świeży). F – incudomalleal joint.

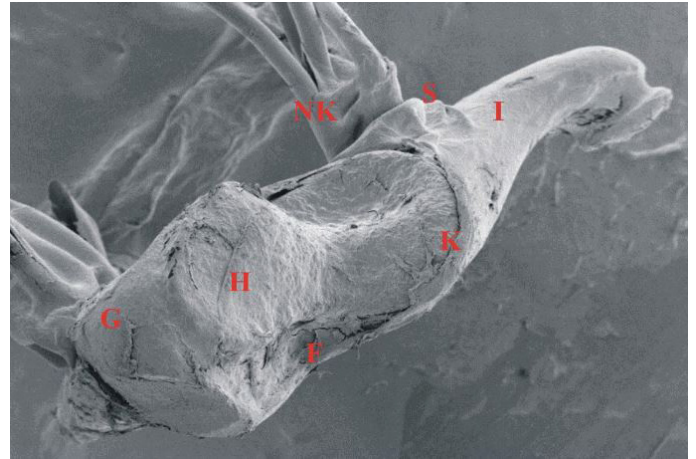
surface of the ossicles. According to the authors, exposure of the ossicular surface was conducive to deep bone erosion. The advanced process of destruction of the bone surface in the case of chronic otitis media (with cholesteatoma or chronic otitis media with

inflammatory granulation) correlated with a substantial degree of damage to the lining covering not only the auditory ossicles, but also surrounding the joint surfaces, although they are not lined by it. Statistically, the presence of rich vasculature in the






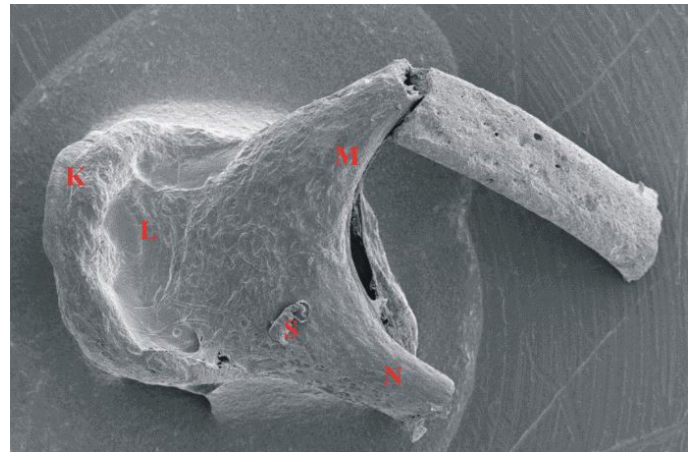
**Fig. 7.** Incus, 60x magnification (Scanning Microscopy Laboratory CM UJ K. Świeży). F—incudomalleal joint, S—mucosa.



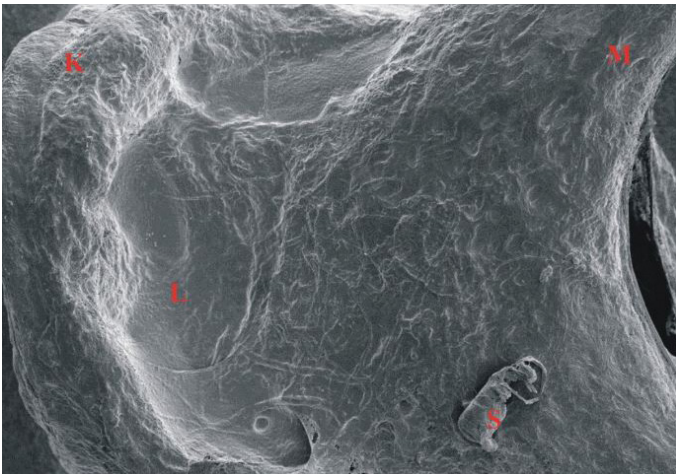
**Fig. 8.** Incus, 20x magnification (Scanning Microscopy Laboratory CM UJ K. Świeży). G—the short crus of incus, H—head of incus, I—the long crus of incus, F—incudomalleal joint, NK—blood vessels, K—mucosal border, S—mucosa.



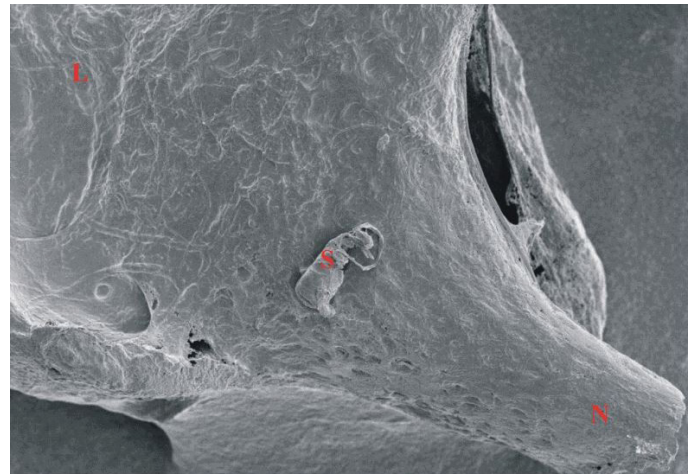
**Fig. 9.** Incus 24x magnification (Scanning Microscopy Laboratory CM UJ K. Świeży). F—incudomalleal joint, S—mucosa.



**Fig. 10.** Stapes—suprastructure, 48x magnification (Scanning Microscopy Laboratory CM UJ K. Świeży). K—head, L—neck, M—anterior crus, N—posterior crus, S—mucosa.



**Fig. 11.** Stapes—suprastructure, 100x magnification (Scanning Microscopy Laboratory CM UJ K. Świeży). K—head, L—neck, M—anterior crus, S—mucosa.



**Fig. 12.** Stapes—suprastructure, 100x magnification (Scanning Microscopy Laboratory CM UJ K. Świeży). L—neck, N—posterior crus, S—mucosa.

I and II auditory ossicles was observed more often than in the analysis of vascularization of stapes. The lack of blood vessels in the assessment of the Electron Microscope in some cases most likely

resulted from the surgical technique of removing elements of the ossicular chain and mechanical damage to the vessels than due to the ongoing inflammatory process. The richer vascularization of

the ossicular chain observed by the authors in the case of chronic otitis media with inflammatory granulation compared to chronic cholesteatoma otitis media requires further investigation on a larger number of preparations.

## DISCUSSION

The auditory ossicles are the only human bones covered with a lining, rather than a layer of osteogenic periosteum. The lining (mucoperiosteum) is characterized by structure and properties similar to the mucosa. The ossicular chain is a mechanical transmission that converts air vibrations into fluid filling the inner ear. Understanding the kinematics of the middle ear ossicles allows designing implants with mechanical properties similar to those of natural ossicles. Based on the observed changes in the Scanning Electron Microscope, disruption of the lining by inflammation promotes advanced bone resorption. Damage to joints (incudomalleal joint, incudostapedial joint), resulting from disruption of joint capsule continuity in the inflammatory process, intensifies the destruction of joint surfaces, favoring disconnection of the ossicular chain and the formation of a significant cochlear reserve. Stapes motion described by G. Békésy in 1936 as rotational along an axis passing through the posterior part of the stapes plate with the largest clearance in the anterior portion is consistent with the anatomy of the annular ligament, which is broader and thinner in the anterior portion of the plate. Disturbance of the anatomical structure of the stapes base with ligament damage (otosclerosis) alters the nature of stapes vibration, disrupting the transmission of sound wave in the middle ear [6–9].

It seems of paramount importance to maintain a balance between individual sections of the ossicular chain in order to maintain appropriate vibration amplitude. Based on kinematic analysis of the ossicular system, reducing the length of the malleus decreases the ratio of stapes vibration amplitude to the amplitude of malleus vibration, while minimizing the incus and stapes length brings the opposite effect [10]. Therefore, at the stage of tympanoplasty of relevant importance is to choose such a reconstruction (from the patient's own material, alloplastic prostheses), whose dimensions will be more akin to the natural sound-conducting chain. This solution allows for the best effect in tonal audiometry and subjective improvement of hearing in the patient [11–14].

Rich vascularization of the ossicular chain supplies individual sections of the conductive system of middle ear, running in the lining sheaths.

The tympanic arteries: superior, lower anterior and posterior, come from various sources and together with the caroticotympanic branch from the internal carotid artery interconnect and form a dense network in the mucosa, from which small branches follow through mucosal folds to the ossicles. Our observations identified that the lining that forms part of the vascular sheaths passes through the continuity to the surface of the ossicles, covering the bone and joint surfaces like periosteum. In no case was the persistent stapes artery, which is a rare congenital anomaly of the middle ear, visible. According to various authors, the incidence of this anomaly is estimated at between 1:4,000 and 1:10,000. In humans, it usually disappears around the 10th week of fetal life. It is usually detected accidentally during stapedotomy or other middle ear surgery.

The unusually rich vascularization of the ossicular chain in the Scanning Electron Microscope demonstrated by the authors shows the important role of physiological vascularization during tympanoplasty. The preservation of blood vessels reduces the risk of degenerative changes of bony elements that could contribute to an imbalance in the proportion of elements of the ossicular chain (length and weight) and result in cochlear reserve on postoperative outcome in remote audiometry. The richer vascularization of the ossicles observed by the authors in the case of chronic otitis media with inflammatory granulation compared to chronic cholesteatoma otitis media indicates exacerbation in local inflammation. Increased angiogenesis is one of the features of the inflammatory process that coexists with the formation of inflammatory infiltrate. The observations made require further investigation on a larger number of preparations [15–18].

## CONCLUSIONS

1. The ossicles in the image of the Scanning Electron Microscope are covered with a lining that passes from the surface of the ossicles to the vascular bundles, forming vascular sheaths;
2. Damage to lining continuity on the surface of the auditory ossicles will benefit the rapid process of destruction of bone tissue in the inflammatory process;
3. The dimensions of individual ossicles are respectively: meatus – 8.36 +/- 0.01, incus – 8.14 +/- 0.0, stapes – 3.23 +/- 0.01 mm. Preservation of the anatomical length of ossicular chain during tympanoplasty appears to be important in maintaining the appropriate vibration amplitude of the conductive system of middle ear.

## REFERENCES

1. Bochenek A., Reichert M.: Anatomia człowieka. Tom 5. Warszawa: Państwowy Zakład Wydawnictw Lekarskich, 1989.
2. Traczyk W.: Fizjologia człowieka w zarysie. Warszawa: Państwowy Zakład Wydawnictw Lekarskich, 1989.
3. Netter F.H.: Atlas of Human Anatomy. CIBA-GEIGY Corporation 1989.
4. Olszewski J., Latkowski B., Zalewski P.: Morphométrie des osselets de l'ouïe pendant le développement individuel de l'homme et son utilité pour cophochirurgie. Cahiers d'O.R.L (Montpellier), 1987; 22(70): 488–492.
5. Kukuła K.: Elementy statystyki w zadaniach. PWN, Warszawa 1998.
6. Hüttenbrink K.B., Pfautsch M.: The ear ossicle joints in the scanning electron microscopy image Laryngol Rhinol Otol (Stuttg.), 1987; 66(4): 176–179.
7. Chen H., Okumura T., Emura S., Shoumura S.: Scanning electron microscopic study of the human auditory ossicles. Ann Anat., 2008; 190(1): 53–58.
8. Zenev I., Zenev E., Sapundzhiev N., Milkov M., Marev D.: Scanning Electron Microscopy of Auditory Ossicles. Mediterr J Otol, 2006; 3: 112–116.
9. Pośpiech L., Bochnia M., Dziewiszek W.: Experimental joint incus-stapedial injuries in scanning electron microscopy. Otolaryngol Pol., 2004; 58(1): 79–84.
10. Marszałik D.: Iwaniec Kinematyka słyszenia – ucho środkowe. Aktualne Problemy Biomechaniki, 2010; 4: 137–141.

11. Wiatr A., Składzień J., Świeży K., Wiatr M.: A Biochemical Analysis of the Stapes. *Med Sci Monit.*, 2019; 12(25): 2679–2686.
12. Masali M., Cremasco M.: Hoc alterum auditus organi ossiculum est: Ear Ossicles in Physical Anthropology. *Human Evolution*, 2006; 21: 1–17.
13. Liu Y., Li S., Sun X.: Numerical analysis of ossicular chain lesion of human ea., *Acta Mech Sin.*, 2009; 25: 241–247.
14. Zhao F., Koike T., Wang J., Sieng H., Meredith R.: Finite element analysis of the middle ear transfer functions and related pathologies. *Medical Engineering & Physics*, 2009; 31: 907–916.
15. Kotzias S.A., Seerig M.M., Mello M.F.P.C., Chueiri L., Jacques J. et al.: Ossicular chain reconstruction in chronic otitis media: hearing results and analysis of prognostic factors. *Braz J Otorhinolaryngol.*, 2020; 86(1): 49–55.
16. Proctor B.: *Surgical anatomy of the ear and temporal bone*. Thieme, New York 1989.
17. Boroń A., Wiatr A., Składzień J., Wiatr M.: The effect of preserved stapedial superstructure on hearing improvement. *Otolaryngol Pol.*, 2019; 74(1): 1–5.
18. Li J., Chen K., Li C., Yin D., Zhang T. et al.: Anatomical measurement of the ossicles in patients with congenital aural atresia and stenosis. *Int J Pediatr Otorhinolaryngol.*, 2017; 101: 230–234.

---

Word count: 2380

Tables: 3

Figures: 12

References: 18

---

DOI: 10.5604/01.3001.0014.1373 Table of content: <https://otolaryngologypl.com/issue/13165>

---

Copyright: Some right reserved: Polish Society of Otorhinolaryngologists Head and Neck Surgeons. Published by Index Copernicus Sp. z o.o.

---

Competing interests: The authors declare that they have no competing interests.

---



The content of the journal „Polish Society of Otorhinolaryngologists Head and Neck Surgeons” is circulated on the basis of the Open Access which means free and limitless access to scientific data.

---



This material is available under the Creative Commons – Attribution 4.0 GB. The full terms of this license are available on: <http://creativecommons.org/licenses/by-nc-sa/4.0/legalcode>

---

Corresponding author: Maciej Wiatr (ORCID: 0000-0003-0840-9268); Faculty of Medicine, Jagiellonian University Collegium Medicum, Poland; E-mail: [maciej.wiatr@uj.edu.pl](mailto:maciej.wiatr@uj.edu.pl)

---

Cite this article as: Wiatr A., Składzień J., Wiatr M.: Auditory ossicles in Scanning Electron Microscopy; *Otolaryngol Pol* 2020; 74 (4): 1-7

---

