

Juvenile nasopharyngeal angiofibroma – 20 years of experience in endoscopic treatment

Authors' Contribution:
A – Study Design
B – Data Collection
C – Statistical Analysis
D – Data Interpretation
E – Manuscript Preparation
F – Literature Search
G – Funds Collection

Witold Szyfter^{1ADEF}, Andrzej Balcerowiak^{1BF}, Wojciech Gawęcki^{1E}, Robert Juszkat^{2B},
Małgorzata Wierzbicka^{1,3A}

¹Department of Otolaryngology and Laryngological Oncology, Poznan University of Medical Sciences, Poland;
Head: prof. Małgorzata Wierzbicka MD PhD

²Department of General and Procedural Radiology of the Poznan University of Medical Sciences, Poland; Head: prof. Robert Juszkat PhD

³Institute of Human Genetics of the Polish Academy of Sciences, Poland

Article history: Received: 31.10.2020 Accepted: 13.11.2020 Published: 18.11.2020

SUMMARY:

Introduction: Juvenile nasopharyngeal angiofibroma is a rare, benign tumor; however, it shows local aggression and leads to profuse nosebleeds.

Aim: The aim of the study is to present 20 years of experience in endoscopic treatment of this tumor.

Material and methods: The material covers 71 patients treated in the years 1985–2019 at the Department of Otolaryngology and Laryngological Oncology in Poznań. In these patients, either the classic external approach, or the double approach – external with the use of endoscopes, or only the endoscopic approach was used. In the entire population, external surgeries were performed in 37 patients, double access in 8 and endoscopic access in 26 patients.

Results: Complete resection of the tumor was achieved in 51 patients (72%). The remaining 20 patients (28%) had a residual or recurrent tumor and all of these patients underwent reoperation.

Conclusions: The endoscopic approach with the use of various optics and navigation allows for the removal of not only small tumors but also much more advanced ones. Pre-operative evaluation of imaging results is extremely important to avoid incomplete tumor removal. Individual development of an operating strategy, a wide range of optics and various surgical methods, and especially endoscopic ones, are the guarantee of therapeutic success.

KEYWORDS:

endoscopy, juvenile nasopharyngeal angiofibroma, surgical treatment

ABBREVIATIONS

CT – computed tomography

JNA – Juvenile nasopharyngeal angiofibroma

MRI – magnetic resonance imaging

INTRODUCTION

Juvenile nasopharyngeal angiofibroma (JNA) is a rare and locally aggressive benign tumor. The infiltration process may involve the bones in the skull, especially the sphenoid bone, which is difficult to remove, and which might be the cause of recurrence. Despite the benign structure of the tumor, it can be life-threatening due to severe bleeding and destruction of intracranial structures [1]. It probably develops from fibrocartilage embryonic tissue in the pterygoid canal between the sphenoid sinus and the pterygoid process of the sphenoid. JNA gradually spreads to the spheno-palatal opening and continues to the nasopharynx, nasal cavity, paranasal sinuses, orbits and the base of skull with temporal and frontal lobe involvement, especially around the cavernous sinus and the carotid siphon [2–4]. Some authors report that tumor growth may occur in leaps and bounds [5, 6]. This tumor represents merely 0.05% of all head and neck neoplasms, and is most common in India, Egypt and Middle East countries [5].

Glad et al. published data regarding the frequency of this lesion in Denmark over the period 1981–2003. They recognized an occurrence in 0.4 patients per 1 million inhabitants annually and 3.7 patients per 1 million male inhabitants. There were no females among 45 patients included in the study [1].

It is important that the preparation for surgical treatment involves the assessment of tumor vasculature. It originates mainly from the external carotid artery and its branches, especially from the maxillary artery. However, as the tumor grows, additional vessels extend from the branches of the internal carotid artery, which are found in approximately 20–25% of patients. As many as 30–40% cases of extensive tumors can involve bilateral vascularization. This is clinically significant for planning preoperative embolization. There is frequently a need for bilateral carotid angiography and, depending on the result, embolization on both sides [5, 7, 8].

Surgical procedures are the generally accepted therapeutic form of treating juvenile angiofibromas [9–11]. For decades various forms of external approaches to these tumors have developed – transfacial, infracranial, subtemporal, sublabial, transpalatal, etc. [12]. In the late 1990s the first reports on the use of endoscopes in the treatment of these tumors emerged [13–15]. Initially, this method was only used to remove small tumors. The introduction of navigation, new

Tab. I. Characteristics of operated patients depending on the location and extent of tumor –based on the classification by Radkowski et al.

| DEGREE OF ADVANCEMENT | NUMBER OF PATIENTS |
|-----------------------|--------------------|
| IA | 3 |
| IB | 6 |
| IIA | 11 |
| IIB | 14 |
| IIC | 18 |
| IIIA | 15 |
| IIIB | 4 |

endoscopes, embolization procedures, and new imaging techniques gradually allowed for the removal of tumors of increasing size, spreading outside the nasal cavity and nasopharynx [7, 10, 12]. Especially useful was also the four-hand technique in which one surgeon uses an endoscope, while the other has both hands free and uses resection tools. In this method, it is possible to introduce an endoscope through a healthy nasal cavity and transition to the affected side. Many years of experience with the endoscopic technique enable understanding that these tumors require individual planning of approaches to the tumor, depending on its size and location, e.g. double external and endoscopic approach or multicorridor approach in combination with neurosurgical access [16–21].

The paper aims to present 20 years of experience at the Clinic of Otolaryngology and Laryngological Oncology in Poznań in the use of endoscopic-guided access in treating juvenile angiofibromas and its comparison with classical methods.

MATERIAL AND METHODS

Over the period 1985–2019, 71 patients with juvenile angiofibroma were treated at the Poznań Clinic. The patients were all male and their ages ranged from 9 to 34 years, with a definite advantage for the 11–19 age group. The only 34-year-old patient had previously been treated many times in various Polish centers from the age of 12. In all patients, histopathological examination revealed the presence of angiofibroma.

The patients were divided into two groups:

- A – 31 patients treated in the years 1985–1999,
- B – 40 patients treated in the years 2000–2019.

This division resulted from several reasons. The first group (A) included patients in whom:

1. preoperative imaging diagnostics involved computed tomography (CT) almost exclusively [and only in a few cases – magnetic resonance imaging (MRI)],
2. blood vessels supplying the tumor were not embolized before the procedure,
3. the operation was always performed from an external approach.

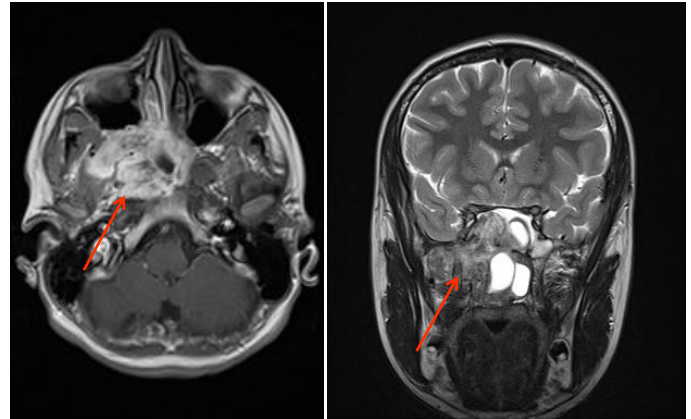


Fig. 1. Juvenile angiofibroma stage IIIA on the right side (arrow) – magnetic resonance imaging.

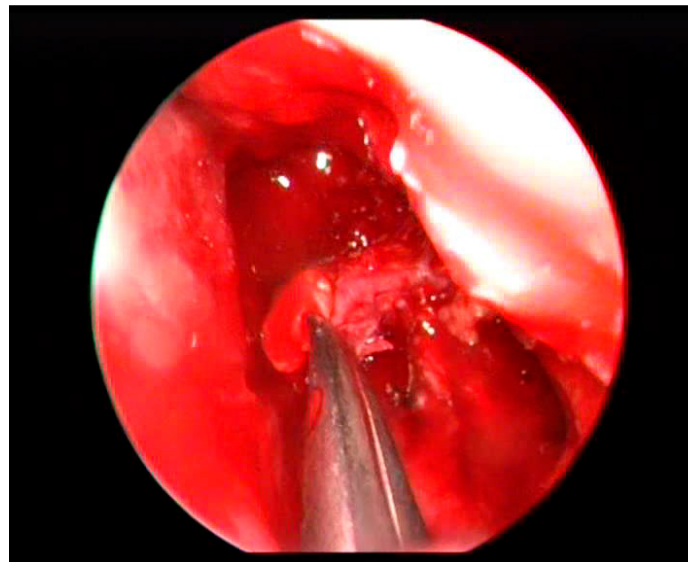


Fig. 2. Endoscopic image of the left nasal cavity – coagulation of the maxillary artery.

The second group (B) included patients who underwent both MRI and CT scans, and, if necessary, tumor embolization. In this group, external, double and endoscopic approaches were used.

Tumors were divided based on the classification by Radkowski et al. from 1996 [22], which allowed to obtain the characteristics of all patients depending on the location and the extent of the tumor. Tab. I. presents this typology and demonstrates that our material was dominated by large and very large tumors occupying at least the pterygopalatine fossa.

In 2000, we started using endoscopes for the excision of JNA. Initially, they were low stage IA and IB tumors, and later – using endoscopes in parallel with an external access – we noticed that the optics gave us a much better assessment of the surgical field, especially in determining the boundary where a tumor meets normal tissue. Each procedure was preceded by a detailed MRI and CT image analysis (Fig. 1.). MRI allowed us to assess the tumor extent and its penetration to the skull base, the meninges, orbit, etc., and the CT enabled assessment of bone damaged by the tumor. As experience was gained in this regard, we increasingly used only the endoscopic technique.

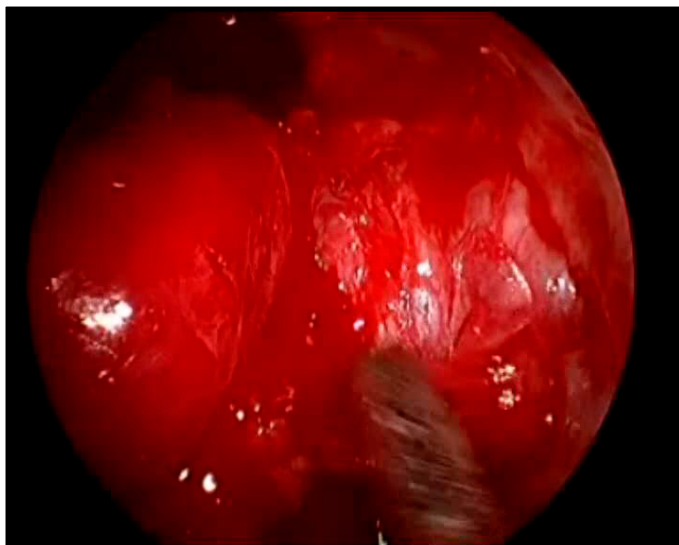


Fig. 3. Endoscopic image of the tumor's lateral protrusion in the pterygopalatine fossa (left side).

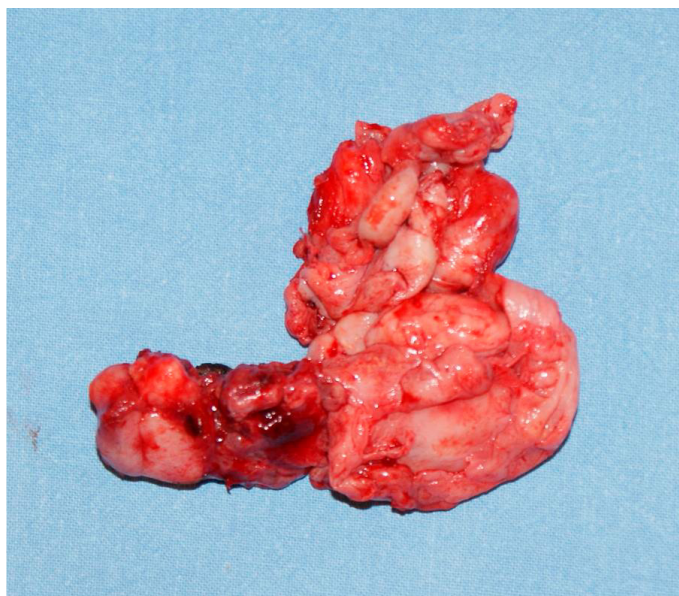


Fig. 4. Surgical specimen of tumor involving: nasopharynx, nasal cavity, ethmoid and maxillary sinuses with a large protrusion in the pterygopalatine fossa partially extending into the subtemporal fossa – right side (tumor removed via a double approach).

Gradually, we developed the following surgical workflow with an endoscope, which is still used in the clinic today and involves a number of stages below.

Stage I – good visualization of tumor with maximum preservation of anatomical structures

The first step is to perform conchoplasty of the inferior turbinate on the tumor side. In the case of extensive deviations of the nasal septum and the lack of full operational comfort, we remove its osteochondral elements, leaving the cartilage for reimplantation. Further steps depend on the tumor size and consist of reducing or often removing the middle turbinate, opening the anterior and posterior ethmoid cells, and the anterior wall of the sphenoid sinus. In the case of

Tab. II. Surgical accesses used depending on the tumor advancement.

| DEGREE OF ADVANCEMENT | NUMBER OF PATIENTS | EXTERNAL APPROACH | DOUBLE APPROACH | ENDOSCOPIC APPROACH |
|-----------------------|--------------------|-------------------|-----------------|---------------------|
| IA | 3 | 0 | 0 | 3 |
| IB | 6 | 1 | 1 | 4 |
| IIA | 11 | 4 | 1 | 6 |
| IIB | 14 | 9 | 1 | 4 |
| IIC | 18 | 11 | 1 | 6 |
| IIIA | 15 | 9 | 3 | 3 |
| IIIB | 4 | 3 | 1 | 0 |
| Total | 71 | 37 | 8 | 26 |

lateral penetration of the tumor, we perform internal maxillectomy and visualize it in the pterygopalatine or subtemporal fossa. In these situations, the endoscope has an advantage over the eye armed only with a microscope or a surgical loupe. Sometimes, especially with a damaged posterior portion of the nasal septum, the endoscope is inserted into the healthy nasal cavity, and in the absence of damage to the septum, it must be incised.

Stage II – the decision to proceed with tumor removal

At this stage of surgery, the navigation system it is very useful to define the boundaries of the lesion from the top, side and medially. For this purpose, we use a navigated suction tube.

Stage III – removal of tumor

In the endoscopic technique, the tumor is most often removed gradually, piece by piece, and so we move deeper, controlling bleeding with bi- and monopolar coagulation. Efforts should be made to keep the surgical site fairly dry in order to clearly visualize the tumor edges and bone access. It is also reasonable to dissect the maxillary artery, coagulate it, or apply a vascular clip (Fig. 2.). Depending on the site, endoscopes with adjustable viewing angles are used. Then we use navigation. In the case of extensive tumors above IIC, efforts are made to find the dura mater. Most often, the tumor does not infiltrate it, but only lifts it and shapes it on itself. We are looking for a plane to submucosal separate the tumor or to separate it from the dura. First, the tumor is removed from the nasal cavity and paranasal sinuses, then from the pterygopalatine fossa and subtemporal fossa (lateral protrusions) and from the nasopharynx (Figs. 3., 4.).

Stage IV – removal of bones suspected of tumor infiltration on the basis of imaging appearance

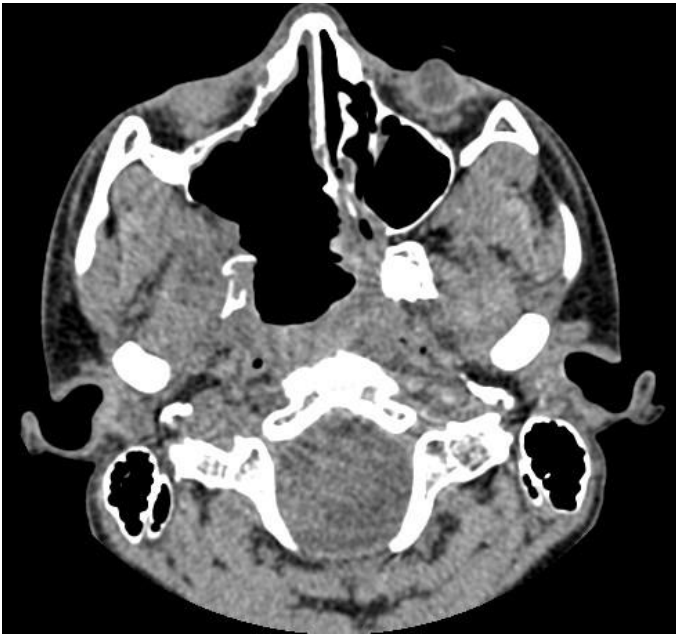
For this purpose, we use diamond drill bits on a long contra-angle to control the condition of the dura mater and the removed bone.

Stage V – final steps

The final steps include covering the exposed dura with material from the patient's tissues and using a tissue adhesive.

Tab. III. The number of residual tumors and recurrences depending on the stage of tumor and the surgical approach (recurrences are marked with the letters Rec).

| DEGREE OF ADVANCEMENT | NUMBER OF PATIENTS | RESIDUAL TUMOR/ RECURRENCE (REC) | EXTERNAL APPROACH | DOUBLE APPROACH | ENDOSCOPIC APPROACH |
|-----------------------|--------------------|-------------------------------------|--------------------|--------------------|---------------------|
| IA | 3 | 0 | 0 | 0 | 0 |
| IB | 6 | 0 | 0 | 0 | 0 |
| IIA | 11 | 0 | 0 | 0 | 0 |
| IIB | 14 | 3 | 2 | 1 | 0 |
| IIC | 18 | 7 | 3 | 2 | 2 |
| IIIA | 15 | 8 (including 3Rec) | 3 (including 2Rec) | 2 (including 1Rec) | 3 |
| IIIB | 4 | 2 | 2 | 0 | 0 |

**Fig. 5.** Follow-up computed tomography performed 6 months after the excision of juvenile angiofibroma on the right side – tumor removed completely.

Tab. II. presents a list of different routes of approaches to JNA depending on the tumor size and location. External approaches were used exclusively in the years 1985–1999, followed later by various techniques, with a predominance of endoscopic ones.

RESULTS

The tumor was completely resected in 51 patients (72%) (Fig. 5). The remaining 20 patients (28%) had a residual or recurrent tumor. It is very difficult to distinguish between these two states, whereby the only criterion is the time from surgery. It is assumed that if a tumor was detected in imaging tests 6 months after the procedure, it is a residual one, and a later diagnosis is considered a local recurrence. Thus, a residual tumor was found in 17 patients (24%) and a local recurrence in 3 (4%).

Tab. III. summarizes the specimen from residual and recurrent tumors depending on the size of the primary lesion and the surgical method.

All these patients were re-treated surgically: 10 from an external approach, 5 from an endoscopic-supported external approach, and 5 from

an endoscopic approach only. In 15 patients, the tumor was completely resected, and in 5, the presence of neoplasm was found in another imaging examination after reoperation and the patients underwent further surgery. One of the patients was operated 12 times at another centers and underwent radiotherapy. He had undergone 2 operations at our center, but with a quick resumption of the neoplastic process. Histopathological assessment of specimens from the last 5 surgeries did not confirm the malignant transformation to a sarcoma in this patient [23, 24].

Additionally, blood loss during surgery was analyzed depending on the size of tumor, embolization performed and the approach for the resection. In stages IA–IIB, endoscopic access combined with embolization in some patients led to minor bleeding with loss of 100–400 ml of blood. In stages IIC–IIIB, despite embolization, the bleeding was more extensive, with loss of 500–2500 ml of blood. To our estimation, it was less abundant during endoscopic removal of the tumor.

DISCUSSION

After being used globally for over 25 years, endoscopic access to JNA is now the accepted method for treating not only small but also advanced tumors [11, 19, 25]. Compared to external methods, it does not lead to a series of unpleasant consequences, such as: facial scars, facial asymmetry, sensory disturbances and palatal fistulas.

In our material, we observed less blood loss than in the case of transfacial surgeries. This is also confirmed by other sources [7, 20, 25]. Thanks to the endoscopic method, which was originally reserved for small tumors, it is now possible to safely reach the deep structures of the skull, gradually removing the tumor. It seems that the cause of recurrence of these benign tumors has been solved. Lyod et al. [26] distinguished two types of bone destruction by JNA. The first type is the outcome of the pressure exerted by the tumor, and the second is related to the deep infiltration of the spongy layer of the skull bone. Precisely this mechanism could explain, fortunately in a few cases, the recurrence of this neoplasm [27–31]. The observations of Lyod et al. suggest, in selected cases, and based on imaging studies, to remove the part of the sphenoid suspected of tumor infiltration with a drill.

CONCLUSION

Summarizing the past experience of numerous JNA operating teams, it seems that the best option is to treat each patient individually. Prior to commencing surgery, a strategy should be developed in consultation with a neuroradiologist assessing MRI and

CT images. Since we are dealing with a benign tumor, it is time to thoroughly prepare for the procedure, preferably endoscopic, with a broad selection of optics and navigation. Despite all the technological advance, better and better apparatus, as well as intra- and postoperative care, juvenile angiofibroma surgery remains a major and difficult operation.

REFERENCES


- Glad H, Vainer B, Buchwald C, Petersen B.L., Theilgaard S.A. et al.: Juvenile nasopharyngeal angiofibromas in Denmark 1981–2003: diagnosis, incidence, and treatment. *Acta Otolaryngol.*, 2007; 127: 292–299.
- Rowan N.R., Zwagerman N.T., Heft-Neal M.E., Gardner P.A., Snyderman C.H.: Juvenile Nasal Angiofibromas: A Comparison of Modern Staging Systems in an Endoscopic Era. *J Neurol Surg B Skull Base.*, 2017; 78: 63–67.
- Alshaiikh N.A., Eleftheriadou A.: Juvenile nasopharyngeal angiofibroma staging: An overview. *Ear Nose Throat J.*, 2015; 94: 12–22.
- Li W., Ni Y., Lu H., Hu L., Wang D.: Current perspectives on the origin theory of juvenile nasopharyngeal angiofibroma. *Discov Med.*, 2019; 27: 245–254.
- Mehan R., Rupa V., Lukka V.K., Ahmed M., Moses V. et al.: Association between vascular supply, stage and tumour size of juvenile nasopharyngeal angiofibroma. *Eur Arch Otorhinolaryngol.*, 2016; 273: 4295–303.
- Pandey P., Mishra A., Tripathi A.M., Verma V., Trivedi R. et al.: Current molecular profile of juvenile nasopharyngeal angiofibroma: First comprehensive study from India. *Laryngoscope*, 2017; 127: E100–E106.
- Janakiram T.N., Sharma S.B., Panicker V.B.: Endoscopic Excision of Non-embolized Juvenile Nasopharyngeal Angiofibroma: Our Technique. *Indian J Otolaryngol Head Neck Surg.*, 2016; 68: 263–269.
- Tyagi I., Syal R., Goyal A.: Recurrent and residual juvenile angiofibromas. *J Laryngol Otol.*, 2007; 121: 460–467.
- Leong S.C.: A systematic review of surgical outcomes for advanced juvenile nasopharyngeal angiofibroma with intracranial involvement. *Laryngoscope.*, 2013; 123: 1125–1131.
- Nicolai P., Schreiber A., Bolzoni Villaret A.: Juvenile angiofibroma: evolution of management. *Int J Pediatr.*, 2012; 2012: 412545.
- Bertazzoni G., Schreiber A., Ferrari M., Nicolai P.: Contemporary management of juvenile angiofibroma. *Curr Opin Otolaryngol Head Neck Surg.*, 2019; 27: 47–53.
- Boghani Z., Husain Q., Kanumuri V.V., Khan M.N., Sangvhi S. et al.: Juvenile nasopharyngeal angiofibroma: a systematic review and comparison of endoscopic, endoscopic-assisted, and open resection in 1047 cases. *Laryngoscope*, 2013; 123: 859–869.
- Tseng H.Z., Chao W.Y.: Transnasal endoscopic approach for juvenile nasopharyngeal angiofibroma. *Am J Otolaryngol.*, 1997; 18: 151–154.
- Nicolai P., Berlucchi M., Tomenzoli D., Cappiello J., Trimarchi M. et al.: Endoscopic surgery for juvenile angiofibroma: when and how. *Laryngoscope.*, 2003; 113: 775–782.
- Scholtz A.W., Appenroth E., Kammen-Jolly K., Scholtz L.U., Thumfart W.F.: Juvenile nasopharyngeal angiofibroma: management and therapy. *Laryngoscope.*, 2001; 111: 681–687.
- Liu J.K., Husain Q., Kanumuri V., Khan M.N., Mendelson Z.S. et al.: Endoscopic graduated multiangle, multicorridor resection of juvenile nasopharyngeal angiofibroma: an individualized, tailored, multicorridor skull base approach. *J Neurosurg.*, 2016; 124: 1328–1338.
- Gołabek W., Szymańska A., Szymański M., Czekańska-Chehab E., Jargiełło T.: Juvenile nasopharyngeal angiofibroma with intracranial extension – diagnosis and treatment. *Otolaryngol Pol.*, 2020; 74: 1–7.
- Gołabek W., Szymańska A., Morshed K.: Transnasal microscopic approach for juvenile nasopharyngeal angiofibroma. *Otolaryngol Pol.*, 2018; 72: 31–36.
- Szyfter W., Popko M., Borucki Ł.: Outcomes of endoscopic surgery, endoscopic-assisted surgery and open surgery in the treatment of juvenile nasopharyngeal angiofibroma. *Videosurgery and other miniinvasive techniques*, 2009; 4: 138–146.
- Llorente J.L., López F.: The endoscopic endonasal approach for the treatment of juvenile angiofibromas. *Acta Otorrinolaringol Esp.*, 2019; 70: 136–144.
- Szyfter W., Popko M., Leszczyńska M., Gawęcki W.: Exclusively endoscopic approach for juvenile angiofibroma in an adult – a case report. *Videosurgery and other miniinvasive techniques*, 2010; 5: 107–109.
- Radkowski D., McGill T., Healy G.B., Ohlms L., Jones D.T.: Angiofibroma: changes in staging and treatment. *Arch Otolaryngol Head Neck Surg.*, 1996; 122: 122–129.
- Chakraborty S., Ghoshal S., Patil V.M., Oinam A.S., Sharma S.C.: Conformal radiotherapy in the treatment of advanced juvenile nasopharyngeal angiofibroma with intracranial extension: an institutional experience. *Int J Radiat Oncol Biol Phys.*, 2011; 80: 1398–1404.
- Reddy K.A., Mendenhall W.M., Amdur R.J., Stringer S.P., Cassisi N.J.: Long-term results of radiation therapy for juvenile nasopharyngeal angiofibroma. *Am J Otolaryngol.*, 2001; 22: 172–175.
- López F., Triantafyllou A., Snyderman C.H., Hunt J.L., Suárez C. et al.: Nasal juvenile angiofibroma: Current perspectives with emphasis on management. *Head Neck.*, 2017; 39: 1033–1045.
- Lloyd G., Howard D., Phelps P., Cheesman A.: Juvenile angiofibroma: the lessons of 20 years of modern imaging. *J Laryngol Otol.*, 1999; 113: 127–134.
- Renkonen S., Hagström J., Vuola J., Niemelä M., Porras M. et al.: The changing surgical management of juvenile nasopharyngeal angiofibroma. *Eur Arch Otorhinolaryngol.*, 2011; 268: 599–607.
- Schreiber A., Bertazzoni G., Ferrari M., Ravanelli M., Rampinelli V. et al.: Management of persistent juvenile angiofibroma after endoscopic resection: Analysis of a single institution series of 74 patients. *Head Neck.*, 2019; 41: 1297–1303.
- Liu Z., Hua W., Zhang H., Wang J., Song X. et al.: The risk factors for residual juvenile nasopharyngeal angiofibroma and the usual residual sites. *Am J Otolaryngol.*, 2019; 40: 343–346.
- Leong S.C.: A systematic review of surgical outcomes for advanced juvenile nasopharyngeal angiofibroma with intracranial involvement. *Laryngoscope.*, 2013; 123: 1125–1131.
- Langdon C., Herman P., Verillaud B., Carrau R.L., Prevedello D. et al.: Expanded endoscopic endonasal surgery for advanced stage juvenile angiofibromas: a retrospective multi-center study. *Rhinology.*, 2016; 54: 239–246.

Word count: 2191 Tables: 3 Figures: 5 References: 31

Access the article online: DOI: 10.5604/01.3001.0014.5220 Table of content: <https://otolaryngologypl.com/resources/html/articlesList?issuelid=0>

Some right reserved: Polish Society of Otorhinolaryngologists Head and Neck Surgeons. Published by Index Copernicus Sp. z o.o.

Competing interests: The authors declare that they have no competing interests

 The content of the journal „Polish Society of Otorhinolaryngologists Head and Neck Surgeons” is circulated on the basis of the Open Access which means free and limitless access to scientific data.



This material is available under the Creative Commons – Attribution-NonCommercial 4.0 International (CC BY-NC 4.0). The full terms of this license are available on <https://creativecommons.org/licenses/by-nc/4.0/legalcode>

Corresponding author Wojciech Gawęcki MD PhD; 1Department of Otolaryngology and Laryngological Oncology, Medical University of Poznan, Poland; Przybyszewskiego street 49, 60-355 Poznan, Poland; Phone: +48 61-8691-387; E-mail: wojgaw@interia.pl

Cite this article as: Szyfter W., Balcerowiak A., Gawęcki W., Juszkat R., Wierzbicka M.: Juvenile nasopharyngeal angiofibroma – 20 years of experience in endoscopic treatment; Otolaryngol Pol 2020; 74: 1-6; DOI: 10.5604/01.3001.0014.5220 (Advanced online publication)
