

# THE EFFECTIVENESS OF MASSAGE FOR TREATING ACNE LESIONS – A CASE STUDY

SZYMON SUWICZAK<sup>1</sup> B,E,F  
• ORCID: 0000-0001-9184-6957

IWONA WILK<sup>1</sup> D,E  
• ORCID: 0000-0003-4914-8391

KRZYSZTOF KASSOLIK<sup>1</sup> A  
• ORCID: 0000-0003-2836-3703

<sup>1</sup> Academy of Physical Education in Wrocław, Faculty of Physiotherapy, Department of Massage and Physical Therapy, Poland

A – study design, B – data collection, C – statistical analysis, D – interpretation of data, E – manuscript preparation, F – literature review, G – sourcing of funding

## ABSTRACT

**Background:** Acne vulgaris is a chronic disease affecting almost 100% of the population. The treatment of this condition is not limited to the disease itself, but also involves eliminating the resultant scars. The most common treatments for acne and the associated scars are pharmacotherapy, cosmetic and physical therapy, and aesthetic medicine therapies. An alternative method for treating this condition may be massage, which, as a mechanical stimulus, may be effective at increasing scar mobility and reducing the pain experienced during movement.

**Aim of the study:** The aim of this case study was to examine the effectiveness of massage for treating the scars resulting from keloid acne.

**Material and methods:** Massage treatments were performed on a young man (32 years old) who, as a result of acne, had scars on the chest and back areas. Massage was performed twice a week for 3 weeks (6 treatments), and each session lasted 40 minutes. Before the therapy, the VAS scale was used to assess the perceived pain, and palpation was used to assess the consistency (hardness) of the post-acne lesions. Skin displacement was measured with the use of an innovative device allowing for determination of the angle of displacement of the superficial skin layer within the scar. A questionnaire was also used to assess well-being and quality of life. The measurements were repeated after each session and immediately after the end of the massage cycle.

**Results:** After a series of massages, the experienced pain, as assessed by the VAS scale, was reduced from level 5 before therapy to level 1 after therapy. Skin mobility was also increased by the massage treatments, and the patient's well-being and quality of life improved after each session.

**Conclusions:** The presented case shows that massage can be used in the treatment of post-acne lesions. This therapy can support the conventional treatment process by contributing to a reduction in pain, increasing the limited mobility and displacement of the scarred skin, and improving overall well-being and quality of life.

**KEYWORDS:** massage, acne lesions, keloid, mobility-shifting of the skin

## BACKGROUND

Acne vulgaris is one of the most common skin diseases, affecting nearly 100% of the population [1]. The mild form of the condition is most frequently observed in 85% of cases, while severe acne affects 15% of individuals [2]. Acne is typically seen in young peo-

ple during adolescence, but it can also occur in adults. This condition affects both genders, although the location of the lesions, the severity of the symptoms, and the duration of the disease can vary. Acne vulgaris is a chronic condition that usually presents in the seboreic areas of the face, chest, and back. The typical lesions include comedones, papules, pustules, purulent

cysts, and scars. It is believed that the pathogenesis of the disease is not homogenous or fully explained, and depends on many different factors [3].

The pathogenic mechanisms involved in acne development are associated with the body's natural immunity, vascular disorders, and involve reactive oxygen species, proteolytic enzymes, UV radiation, and infectious agents. Furthermore, the influence of environmental conditions on immunity may be responsible for the development of various symptoms of the disease [4]. A scar (Latin: cicatrix) refers to a loss of a piece of dermis characterized by replacement of the loss with fibrous connective tissue. Scars can result from skin damage during the healing of active acne lesions, and scarring is always associated with advanced acne and a delayed healing processes. Scars may be either hypertrophic (keloid scar), occurring when the amount of connective tissue is greater than the amount of tissue destroyed by the injury, or atrophic [5].

The impact of acne vulgaris on the individual can be quite complex, concerning not only the visible changes on the body, but also the potential development of psychological disorders and social problems. The sense of shame and embarrassment associated with this condition often results in the abandonment of social life or participation in various forms of recreation, thus severely affecting the quality of life [6]. The widespread debilitating effects of this disease on young people resulted in the establishment of a worldwide support group (ASG – Acne Support Group) in 2004 with headquarters in England [7]. The main goals of this group are to support young people in the fight against acne, and to educate individuals on new therapeutic techniques and coping strategies.

The clinical picture of acne is also diverse. Several types of acne are distinguished depending on the type of lesions present and the age of onset. According to the type of lesions, acne may be categorized as papulous, pustular, papulopustular, phlegmonous, conglobata, or keloid [8]. One can also distinguish between baby acne, teen acne, and adult acne. Baby acne includes closed blackheads and small pimples, caused by the temporary action of the mother's hormones. This subtype of acne disappears quite quickly and then returns at puberty. In many cases, seborrhea and the first comedones occur in 11 to 12-year-old children at the onset of puberty [3]. Unusual forms of acne include the so-called acne inversa located on the buttocks, around the anus, under the arms, or in the groin region. The primary symptom of this condition is a painful nodule that bursts and creates a fistula with purulent fluid [2]. We may also distinguish hormonal acne as a symptom of polycystic ovarian syndrome, acne caused by cosmetics containing lanolin, Vaseline, or mineral oils, drug-induced acne resulting from the use of steroid drugs, acne due to irritation or stress, perimenopausal acne, and occupational

acne resulting from continuous contact with greases and industrial oils [4, 6, 9-10].

The treatment of acne scars is challenging, as each type of scar has a different cause and structural setup, requiring a personalized approach to the lesion. Selected invasive procedures can be used for acne lesions, such as laser surgery, which involves the use of a special CO<sub>2</sub> laser to vaporize the lesion tissue [11]. Another treatment involves diathermy or radio frequency waves, which had its beginnings in cosmetology [12-13]. The stimulation of physiological processes, fiber shrinkage, and the stimulation of fibroblasts to create new normal collagen, techniques developed to delay skin aging processes, have also proven to be useful in the treatment of post-acne lesions [14]. In the case of various types of scars, including post-acne scars, dermabrasion procedures consisting of exfoliation of the superficial layer of the skin using a special device with fine exfoliating crystals are applied [15].

Another treatment for acne scars is skin needling, also known as microneedling or collagen induction therapy. This noninvasive, nonsurgical, and nonablative technique involves the use of a microneedling device to create controlled skin damage [16]. The controlled damage triggers repair processes in the skin to fill the micro-wounds by producing new collagen and elastin in the papillary layer of the dermis. This treatment also induces new capillaries to form. The process of neovascularization and neocollagenesis after microneedling treatment leads to scar reduction and skin rejuvenation by improving skin structure, firmness, and hydration [3,17]. The most invasive, but also the most effective method, for reducing acne scars is "subcision" or "cutting". The subcision procedure is performed to completely reduce post-traumatic or atrophic scars that are the remnants of inflammation due to acne vulgaris or chickenpox [18-19]. Studies conducted by the National Center for Biotechnology have also examined the introduction of mechanical treatments into the therapies for improving skin function, including the application of massage for the treatment of post-acne lesions [20-22].

## AIM OF THE STUDY

This study aimed to examine the effectiveness of using massage to treat scars on the back and chest of a young man that resulted from a history of teenage acne.

## MATERIAL AND METHODS

A professionally active 32-year-old man who had struggled with acne for 5 years was referred to the dermatology clinic in the Department of Dermatol-

ogy and Venereology at the Military Clinical Hospital in Wrocław for the diagnosis and treatment of acne scars. The patient was examined by a dermatologist, who performed a physical examination and used videodermoscopy to create a digital recording of the condition. The patient's acne scars were located in the area of the upper, anterior trunk, including the chest, and the posterior trunk, including all over the back. The lesions were hypertrophic in appearance, varied in size and depth, and had irregular shapes with a hard texture. Two types of keloids were identified. The first entered the superficial layer of the skin, and the other protruded beyond the skin surface (Figures 1-4). Characteristic pits and bumps with an elongated appearance and uneven outlines and contours were also observed, and the examination revealed the presence of numerous thickenings in the form of blackheads.

The patient was first treated conservatively with tetracyclines, which have antibacterial and anti-inflammatory effects, and help to reduce skin irritation. The drug was taken orally at a daily dose of 300 mg for 12 weeks. Simultaneously, a topical application of vitamin C was applied once a day. After the end of the treatment period and another visit to the specialist, no significant changes were found, and the decision was made to change the treatment.

At this point, a preparation from the group of vitamin A retinoids (isotretinoinum) was used together with a topical vitamin C ointment once daily. The initial dose prescribed by the doctor was 0.5 mg/kg body weight per day but, due to patient's good drug tolerance, was later increased to 1 mg/kg. However, side effects of malaise, and excessive dryness of the mucous membranes and skin, occurred during this phase of treatment. The therapy lasted for 14 weeks

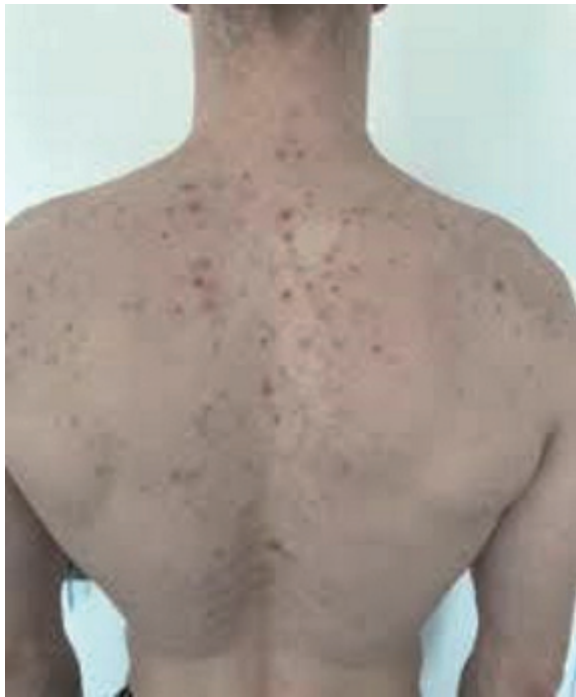

Figure 1. Acne scars on the back before therapy

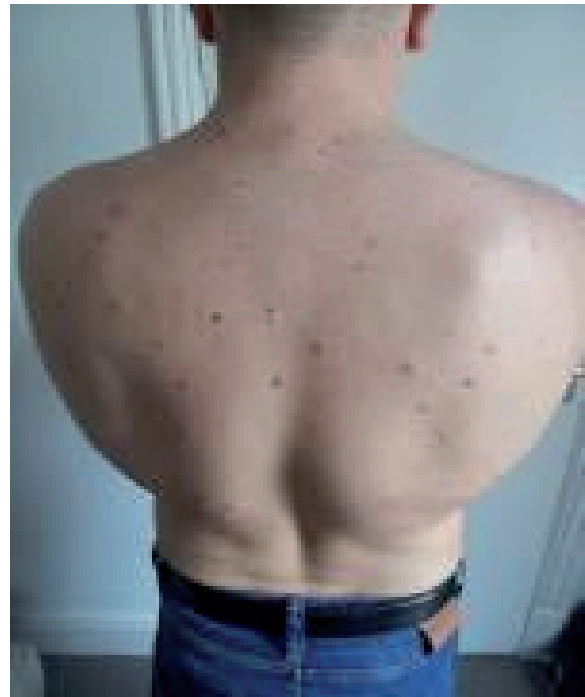


Figure 2. Acne scars on the back after therapy

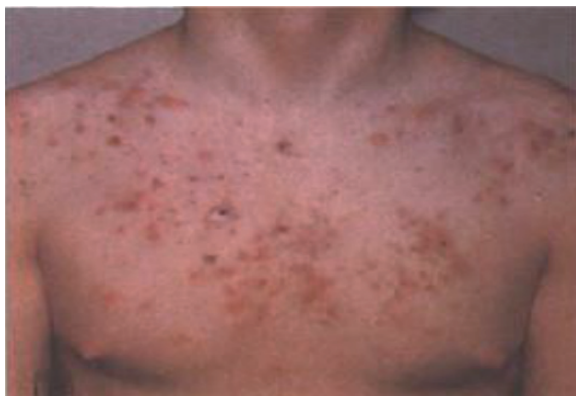

Figure 3. Acne scars on the chest before therapy

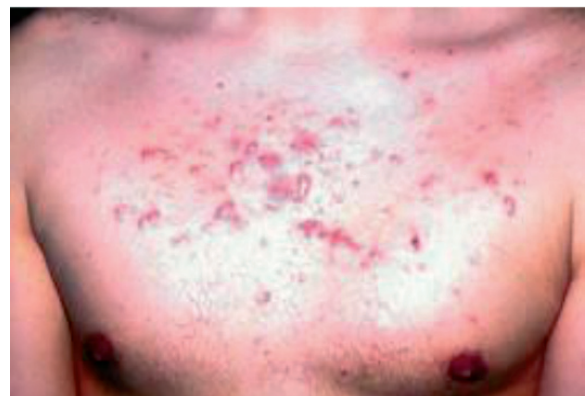

Figure 4. Acne scars on the chest after therapy

and was discontinued. A slight improvement in the disease course was achieved in the form of a change in scar color and reduced pain.

The patient was then offered to participate in a program that planned to apply massage to the affected area. The patient had no history of deep vein thrombosis, myocardial infarction, or cancer within the last 5 years. There were also no genetic defects, and no current acute inflammatory conditions of the respiratory, gastrointestinal, or genitourinary systems. The patient weighed 88 kg and had a height of 170 cm, and, according to a BMI value  $> 30$ , was obese.

Before the massage treatments, the physiotherapist performed an examination. A visual-graphical pain assessment scale (Visual Analogue Scale [VAS]) was used to assess the pain experienced. This scale measures the range of pain sensations from 0 to 10,

where 0 is no pain and 10 is severe pain. A palpation assessment was also performed to determine the hardness and soreness while touching the post-acne lesions. Skin mobility was measured using a specially constructed innovative device to determine the angle of displacement of the superficial layer of the skin around the scar (Figures 5 and 6). The device was used to measure and obtain values in degrees. The scale contained a graduation scale in 1-degree increments from 0 to 180 degrees, thus allowing for the evaluation of displacement. The surface of the apparatus used for the test was round with a special rubber structure, enabling it to interact with the skin surface where acne scars were located, and determine the displacement value. The apparatus also included a comfortable handle for conducting accurate measurements.



Figure 5. The skin mobility massage device (side view)



Figure 6. The skin mobility massage device (top view)

A survey questionnaire assessing subjective well-being and comfort was also used. Before therapy, the patient had a blood test to determine C-reactive protein (CRP) levels to exclude inflammation.

After the diagnostic tests, massage therapy was applied twice a week for 3 weeks (6 treatments) to the areas with acne scars. The treated areas were the back of the trunk (latissimus dorsi muscle, trapezius muscle, rhomboid muscle, supraspinatus muscle, infras-

pinatus muscle) and the thoracic area (pectoral fascia, pectoralis major, pectoralis minor, rectus abdominis, and shoulder muscles). A single massage lasted 40 min, with the first 20 min focused on the chest and the last 20 min focused on the back. The first part of the treatment was performed in the back position (Figure 7), and the second part, including the dorsal preparation, was performed in the front lying position with the proper positioning of wedges (Figure 8).

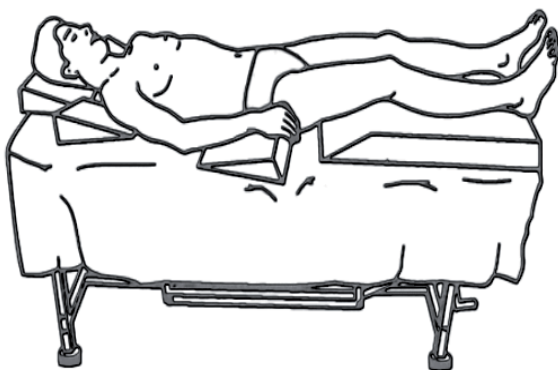


Figure 7. Lying down on the back

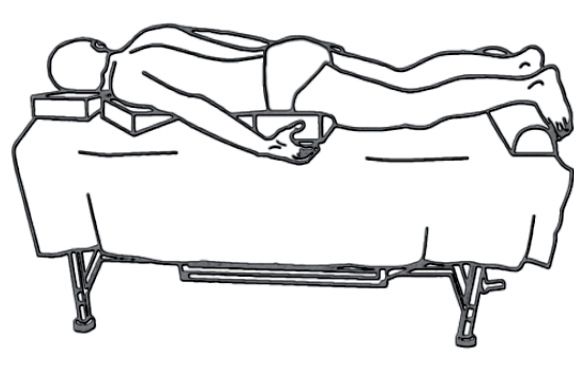


Figure 8. Lying down on the stomach

The treatment began by performing superficial stroking with and against the hair of the entire massaged area. This technique was used to start the treatment and was also applied in the final phase. In the main part of the massage, deep stroking was performed on both the chest and back. A second technique that was used stretched the skin layer by elastic deformation, and an additional technique included transverse and longitudinal kneading performed on individual muscles. A neutral scented non-sensitizing oil approved by a dermatologist was applied during the treatment. After the application of the abovementioned manual techniques, several movements were performed on the skin using the device illustrated in Figures 5 and 6. Circular movements were performed directly on the scar in order to reduce its tactile sensitivity, increase its elasticity, and thereby improve its mobility. This latter technique comprised the main part of the treatment and accounted for 40% of the total massage time. In the final part of the massage, the superficial stroking movements were repeated on the treated body areas.

## RESULTS

One of the questions included in the questionnaire, asked before and immediately after each massage treatment, included the patient's assessment of their quality of life. The results from this question are illustrated in Figure 9. Immediately after each massage treatment the patient felt an improvement in his quality of life. He began the therapy with the description "somewhat dissatisfied" and after the last treatment he described his life of quality as "fully satisfied". Before each subsequent massage, a decrease in quality of life was generally noted, but there was an increasing trend of positive changes in such feelings before each subsequent massage.

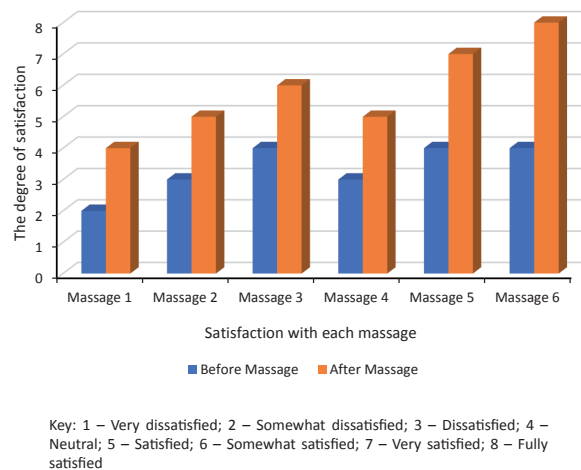


Figure 9. The patient's quality of life before and after each massage session

Figure 10 shows the patient's subjective well-being as measured by a 6-point descriptive scale. The obtained results revealed an improvement in the general well-being of the respondent following treatment. The patient's well-being improved directly after each massage and, although it was decreased before each treatment, at the end of the therapy it was described as "very good". It was also observed that in the middle of the therapy, both before and after the treatment, the mood was described as better as compared to before the start of treatments.

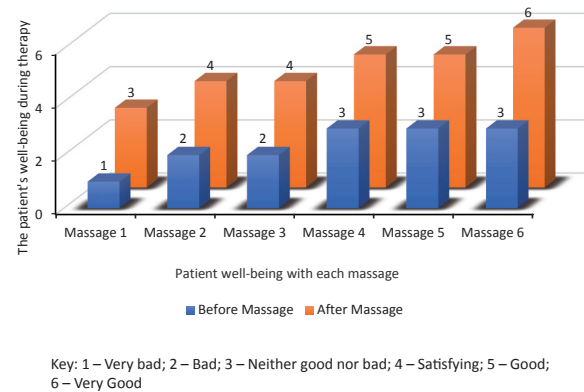


Figure 10. The patient's subjective well-being before and after each massage session

The patient's subjective perception of pain over the course of treatment, as assessed by the VAS scale, is shown in Table 1. The results demonstrate that changes occurred in pain sensations before and immediately after the completion of therapy. Measurements were also taken before and immediately after each session. Before the therapy, the pain was defined as level 3, and after each massage it decreased. However, before the next treatment, pain again was higher, thus indicating the reaction of the skin and scars to the massage. Throughout the therapy, the maximum value on the numerical scale marked by the patient was 5, and at the end of therapy the pain was described as 1.

Table 1. The patient's subjective perception of pain before and after each massage session. (VAS scale)

| Massage treatments | Before massage (VAS scale) | After massage (VAS scale) |
|--------------------|----------------------------|---------------------------|
| Massage 1          | 3                          | 2                         |
| Massage 2          | 4                          | 2                         |
| Massage 3          | 4                          | 2                         |
| Massage 4          | 5                          | 3                         |
| Massage 5          | 5                          | 3                         |
| Massage 6          | 5                          | 1                         |

Before therapy, the affected areas were assessed by palpitation. In this case, it was carried out in the chest and back regions. Palpation of the pectoralis major muscle involved its upper, middle, and lower parts. In each part of the muscle, the assessment was performed on the initial and final attachments (crest of the greater tubercle). The response (pain, pressure sensitivity) to pressure placed on the scar tissue located in the area was also evaluated. On the back, palpation was performed on the trapezius and latissimus dorsi muscles, since they were located within the pathologically changed area. The initial and final attachments of the abovementioned muscles were assessed by palpation. Palpation after the application of a series of massages on the affected areas (chest and back) revealed that, in the localized areas of the scars, the patient had no pain reaction to touch or pressure, as before the therapy. Palpation of the massaged muscle attachments confirmed the absence of pain on the tendon parts and only pressure sensation.

Changes in skin mobility around the scars were also recorded during the therapy (Figure 11). Immediately after each massage, the skin mobility improved by several degrees. However, this effect was temporary and did not last until the next treatment. The greatest change in skin mobility occurred immediately after the second and fifth treatment, amounting to 6 (which means a mobility of 14–15°) without the feeling of “pulling on the skin” (Figure 11).

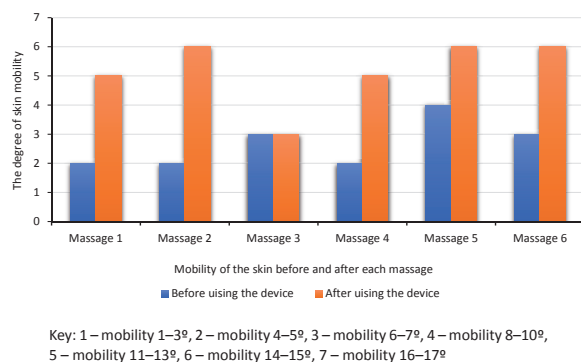


Figure 11. Skin mobility before and after each massage session as measured using a novel device

Before treatment, the patient's CRP level was 9.83 mg/l, thus indicating inflammation in the body. Immediately after the treatments, the CRP level dropped to 6.65 mg/l.

## DISCUSSION

Acne and the occurrence of acne scars are significant clinical and social problems. The high frequency of occurrence defines this condition as a disease of

civilization [3]. Acne scars, in addition to being associated with pain, can reduce skin mobility in the area of the scar, limit the mobility of the affected body region, and can cause a serious problem with self-acceptance. While scars located on the chest and back can be hidden under clothing for most of the year, during the summer months they can become a serious problem for young people who want to expose their body at the beach or pool. On the other hand, acne scars on the face are impossible to hide all year round and attract the attention of, not only peers, but also random individuals. Such a stressful situation occurring over a long period long of time can often lead to social withdrawal, the avoidance of social contacts, and resignation from various forms of physical activity, especially team sports. Indeed, studies have shown that patients treated for advanced and chronic acne disease show a greater tendency towards depression, resulting in a decreased quality of family, professional, and social life [23-29].

In the current case study, the massage-treated patient exhibited a decrease in pain symptoms associated with the scars and increased skin mobility, which directly contributed to an improvement in well-being and quality of life. Given these positive results, it would be advisable to further examine the effectiveness of massage for treating acne scars in a larger group of participants. Indeed, massage would likely be useful as a complementary form of mainstream therapy used for acne scar reduction [30-31].

Multiple studies have previously reported the positive effects of massage on improving blood supply to the skin, skin elasticity, mobility, skin tone, and sensitivity to touch [32-33]. For a long time, massage has been used in cosmetology to prepare the skin for other treatments, including care, regeneration, or tightening. In addition, massage has always been practiced in physiotherapy for therapeutic purposes. In one study, it was shown that massage could lead to increased structural remodeling in the massaged tissue. Under the influence of tissue deformation, angiogenesis and the metabolic activity of fibroblasts, the main cell type responsible for adaptive processes in the tissue, are activated [33-35]. The current case study suggests that a similar mechanism may be involved during the massage of acne scars, and that this therapeutic technique can lead to a structural remodeling of the scar tissue. Other studies have also shown that elastic deformation at a low intensity can induce changes in the different structures of the skin layers [36-37]. Collagen fibers provide the building material for various connective tissue structures, and scar tissue, as a form of connective tissue regeneration, also contains collagen fibers type I, III, V, and IV. Deformation of collagen fibers during massage causes changes in the cells surrounded by them. As a result, an increase in the expression of fibroblast growth

factor (FGF) in the tendon tissue occurs [38-39]. This process, described in detail by many authors, also is another possible mechanism whereby massage may be effective for treating acne scars [40-42]. An additional reason for the use of massage is its analgesic effect [43-44].

It should be emphasized that skin mobility is essential when performing particular movements. Moreover, the skin cooperates with deeper structures (fascia or muscles) during movement. Research has shown that the repeated application of selected massage techniques on a specific body surface significantly improves skin mobility [45]. It has also been shown that rolling contributes to the greatest changes in skin mobility improvement, and that the rubbing technique plays an important role (23% and 18% from the initial state, respectively) [45]. These results further support the validity of using massage to treat acne scars, and indicate that the increased skin mobility produced by this treatment can promote proper movement of the joints, without a feeling of pulling or pain.

## REFERENCES

- Langner A, Ambroziak M, Stąpór, et al. Trądzik pospolity: podstawowe zasady leczenia. *Przew Lek* 2000; 4: 78- 82. (In Polish).
- Mojs E. Choroby skóry w ujęciu psychosomatycznym. *Now Lek* 2010; 6: 483- 486. (In Polish).
- Kaszuba A. Wspomagające i zabiegowe metody leczenia trądziku pospolitego oraz zmian po trądzikowych. *Derm Estet* 2005; 4: 194- 197. (In Polish).
- Placek W, Romańska- Gocka K, Grzanka A. Leczenie miejscowe trądziku. *Przegl Dermatol* 2011; 98: 442- 448. (In Polish).
- Jabłońska S, Majewski S. Choroby skóry i choroby przenoszone drogą płciową. Warszawa: Wydaw. Lekarskie PZWL; 2005. (In Polish).
- Krasowska D. Trądzik. Diagnostyka i leczenie. Lublin: Wydaw. Czelej; 2009: 115- 170. (In Polish).
- Kaszuba A. Leczenie chorób skóry. Wrocław: Wydaw. Elsevier Urban & Partner; 2009: 302- 307. (In Polish).
- Michalak M. Składniki aktywne kontra trądzik. *Cabines Polska* 2012; 54: 34- 39. (In Polish).
- Adamski Z, Kaszuba A. Dermatologia dla kosmetologów. Wrocław: Urban&Partner; 2010: 54- 58. (In Polish).
- Braun-Falco O, Plewig G, Wolff HH, Burdgdorf WHC. Dermatologia. Lublin: Wydaw. Czelej; 2004: 993- 1002. (In Polish).
- Gozali MV, Zhou B. Effective treatments of atrophic acne scars. *J Clin Aesthet Dermatol* 2015; 8: 33- 40.
- Halachmi S, Ben Amitai D, Lapidoth M. Treatment of acne scars with hyaluronic acid: an improved approach. *J Drugs Dermatol* 2013; 12: e121- e123.
- Ellenbogen R. Invited comment on autologous fat injection. *Ann Plast Surg* 1990; 24: 297.
- Lee JB, Chung WG, Kwahck H, et al. Focal treatment of acne scars with trichloroacetic acid: chemical reconstruction of skin scars method. *Dermatol Surg* 2002; 28: 1017-1021.
- Towe KM. Oxygen-collagen priority and the early metazoan fossil record. *Proceedings of the National Academy of Sciences of the United States of America* 1970, 65 (4): 781-788.
- Abraham L, Kierszenbaum A, Tres LL. Histology and cell biology: an introduction to pathology. Elsevier 2020: 141.
- Gozali MV, Zhou B. Effective treatments of atrophic acne scars. *J Clin Aesthet Dermatol* 2015; 8:33- 40.
- Olska H. Dermatologia w praktyce. Warszawa: PZWL; 2009: 144-148. (In Polish).
- Bowszyc J. Postępy dermatologii. Supplement II do tomu XIII. Poznań 1996; 4, 15. (In Polish).
- Tazbir M. Ocena skuteczności i tolerancji preparatów kosmetycznych przeznaczonych do pielęgnacji skóry trądzikowej. *Derm Estet* 2011; 3: 167- 174. (In Polish).
- Well D. Acne vulgaris. *Nurse Pract* 2013; 38: 22- 31.
- Jacob CI, Dover JS, Kaminer MS. Acne scarring: a classification system and review of treatment options. *J Am Acad Dermatol* 2001; 45: 109- 117.
- Fabbrocini G, Fardella N, Monfrecola A, et al. Acne scarring treatment using skin needling. *Clin Exp Dermatol* 2009; 34: 874- 879.
- Fabbrocini G, Annunziata MC, D'Arco VD, et al. Acne scars: pathogenesis, classification and treatment. *Dermatol Res Pract* 2010; 2010: 893980.
- You HJ, Kim DW, Yoo ES. Comparison of four different lasers for acne scars: resurfacing and fractional lasers. *J Plast Reconst Aesthet Surg* 2016; 69:e87- e95.

## CONCLUSIONS

Massage causes a decrease in the pain experienced around an acne scar, increases skin mobility around the scar, and, improves the sense of well-being and perceived quality of life in patients affected by this condition.

26. Brzeziński P. Niskie dawki izotretynoiny w terapii trądziku zwykłego. *Derm Prakt* 2012; 3: 51- 53. (In Polish).
27. Alam M, Omura N, Kaminer MS. Subcision for acne scarring: technique and outcomes in 40 patients. *Dermatol Surg* 2005; 31: 310-317.
28. Christophel JJ, Elm C, Endrizzi BT, et al. A randomized controlled trial of fractional laser therapy and dermabrasion for scar resurfacing. *Dermatol Surg* 2012; 38: 595-602.
29. Ramesh M, Gopal M, Kumar S, et al. Novel technology in the treatment of acne scars: The matrix-tunable radiofrequency technology. *J Cutan Aesthetic Surg* 2010; 3:97-101.
30. Chua S, Ang P, Khoo L, et al. Nonablative 1450-nm diode laser in the treatment of facial atrophic acne scars in type IV to V Asian skin: a prospective clinical study. *Dermatol Surg* 2004; 30:1287-1291.
31. Błaszczuk-Kostanecka M, Chodynicka B, Gliński W. Trądzik popolity: patogeneza i zasady leczenia. *Przeegl Dermatol* 1998, 85 (1): 3- 19. (In Polish).
32. Kasprzak W, Mańkowska A. Fizykoterapia, medycyna uzdrowiskowa i SPA. Warszawa: PZWL; 2008. (In Polish).
33. Hilgier M. Ból u chorych na nowotwór. Warszawa: PZWL; 2008. (In Polish).
34. Andrzejewski W, Kassolik K, Karaś A, Karaś G, Trzęsicka E. Ocena efektywności masażu medycznego u osób z bólami dolnego odcinka kręgosłupa. *Fizjoter Pol* 2006; 2, (4): 150–156. (in Polish).
35. Dziak A. Bolesny krzyż. Kraków: Medicina Sportiva; 2003. (In Polish).
36. Cherkin D, Sherman K, Deyo R, et al. A review of the evidence for the effectiveness, safety, and cost of acupuncture, massage therapy, and spinal manipulation for back pain. *Ann Intern Med* 2003; 138: 898- 906.
37. Frey Law L, Evans S, Knudtson J, Nus S, Scholl K, Sluka K. Massage reduces pain perception and hyperalgesia in experimental muscle pain: a randomized, controlled trial. *Journal of Pain* 2008; 9, 8: 714–721.
38. Andrzejewski W, Kassolik K, Dziegiel P, Pula B, Ratajczak-Wielgomas K, Jablonska K, et al. Effects of synergistic massage and physical exercise on the expression of angiogenic markers in rat tendons. *Biomed Res Int* 2014; 1-9: doi: 10.1155/2014/878095 Epub 2014 May 12.
39. Kassolik K, Andrzejewski W, Dziegiel P, Jelen M, Fulawka L, Brzozowski M, et al. Massage-induced morphological changes of dense connective tissue in rat's tendon. *Folia Histochem Cytobiol* 2013; 51 (1):103- 106.
40. Pawlak H, Andrzejewski W, Kassolik K. Masaż w współczesnej medycynie. *Rehab Prakt* 2008; 4: 40-43. (In Polish).
41. Andrzejewski W, Rożek-Mróż K, Sikorski B, Podwika M, Majewska B. Wykorzystanie masażu w celu normalizacji napięcia mięśniowego osób z astmą oskrzelową. *Fizjoterapia* 2000; 8 (2): 34- 37. (In Polish).
42. Andrzejewski W, Kassolik K, Pawlak H. Sprężyste odkształcenie tkanek, a rozwój technik masażu. *Rehab Prakt* 2008; 1: 42–44. (In Polish).
43. Guthlin C, Walach H. Die Wirksamkeit der klassischen Massage bei Schmerzpatienten-eine vergleichende Studie. *Physikalische Therapie* 2000; 21: 717–722. (In German).
44. Cooper R. Understanding paraspinal muscle dysfunction in low back pain a way forward? *ARD* 1993; 52: 413–415.
45. Dmochowski S, Andrzejewski W, Kassolik K, Wilk I. Wpływ wybranych technik masażu klasycznego na zmianę przesuwalności skóry. *Rehab w Prakt.* 2014; 6: 63-65. (In Polish).

Word count: 3525

• Tables: 1

• Figures: 11

• References: 45

**Sources of funding:**

The research was funded by the authors.

**Conflicts of interests:**

The authors report that there were no conflicts of interest.

**Cite this article as:**

Suwiczak S, Wilk I, Kassolik K.

The effectiveness of massage for treating acne lesions – a case study.

Med Sci Pulse 2021; 15(2): 52–59. DOI: 10.5604/01.3001.0015.0543.

**Correspondence address:**

Iwona Wilk

Physiotherapy Group,

University School of Physical Education in Wrocław

I.J. Paderewskiego 34 Str.

Wrocław, Poland

E-mail: iwona.wilk@awf.wroc.pl

Received: 31.01.2021

Reviewed: 25.05.2021

Accepted: 30.05.2021