*Bull. Vet. Inst. Pulawy 44, 87-93, 2000*

# LOCALIZATION OF THE AUTONOMIC NERVE CENTRES OF THE UTERINE CERVIX IN DOGS*

STANISŁAW FLIEGER, ZBIGNIEW BORATYŃSKI, ANNA ZACHARKO, BOLESŁAW STRZAŁKA AND ZYGMUNT WRONA

Institute of Animal Anatomy,
Agricultural University,
20-934 Lublin, Poland

The experiment was performed on sexually mature female dogs. Operational procedures were performed according to classical surgical methods in general anaesthesia. The animals were kept alive for 21 days and subsequently put down and sectioned for the following material: the brain stem, the spinal cord with all the spinal ganglia, all the ganglia of the sympathetic trunk and the ganglia and plexuses of abdominal and pelvic cavities. The material was fixed in histological slides. The localization of retrograde changes, presented here, allows certification that the autonomic and afferent nerve fibres supplying the uterine cervix in the female dog originate from the central, as well as, from the peripheral autonomic nervous system.

Key words: autonomic nerve centres, afferent fibres, cervix uteri, female dog.

The problem of regulation of the reproductive system in the female dog may be viewed in two aspects. The first aspect is the regulation of the activities by the means of vegetative nerve centres which innervate the organ, the second one is the hormonal effect on the morphological and functional condition of the reproductive organs or their parts (18,24). Immunocytochemical examinations in recent years proved that the level of various neuropeptides in the neurones may change in various physiological states of the *uterus* (29).

Another problem is the variety of disturbance factors in modulating the activity of the specific internal organs which cause many illnesses of scarcely known etiology occurring in man (3,32) and animals (18,21) and affecting the cells of the autonomic nervous system, causing their degeneration.

In the context of the above, a special role is ascribed to the uterine cervix. Its functions are extremely important both in pregnancy and labour (1,18,20). The latest studies on various aspects of female reproductive organs, including the uterine cervix, were conducted on man (2,3,33), laboratory animals (4,5,8,19,25,27,28,29,31) and in domestic animals such as – sheep (13,17,23,34), pigs (6,7,15,16) and cows (14,18,22).

Based on the fact that cutting the nerve fibres supplying a particular organ causes degenerative changes in the nerve cells of the relevant nerve centres (26), a trial of localizing the nerve centres for the uterine cervix in female dogs was undertaken.

* Supported by Grant № 5PO6K 001 13.

## Material and Methods

The experiments were conducted on 4 sexually mature female dogs of mixed breed. The extirpation of the uterine cervix was performed in 3 animals, while for describing the effect of the operational procedures used the incision of the abdominal wall with the *peritoneum* across the *linea alba* was performed in the remaining animal (control animal). All surgical procedures were performed under general anaesthesia. For premedication, xylazine in the dose of 2 mg/kg of the body weight and atropine in the quantity of 0.05 mg/kg of the body weight were applied. The proper anaesthesia was conducted by the intramuscular injection of ketamine in the quantity of 10 mg/kg of the body weight. After preparing the operational site, the incision was performed in the course of the *linea alba* and cervixes were removed in three experimental animals. *Cervix uteri* was not removed in the control animal. The animals were kept alive for a period of 21 days. Then they were put down and the following material was taken for research: brain stem, spinal cord with its $Th_1$ –$S_3$ spinal ganglia, thoraco-abdomino-pelvic part of the sympathetic trunk with the following ganglia: coeliac, cranial mesenteric, intermesenteric, caudal mesenteric ganglia as well as hypogastric and pelvic plexuses.

The material was fixed in formalin, dehydrated in ethyl alcohol, embedded in paraffin and cut into 15$\mu$m thick sections. The sections were stained according to Nissel`s and Klüver –Barrera`s method.

## Results

The experiments conducted caused degenerative changes in the nervous cells of the experimental animals both in the central as well as in the peripheral nervous systems.

Degenerated cells appeared in the structures of the central and peripheral nervous system - spinal cord, brain stem *(medulla oblongata)*, sympathetic trunk, in some ganglia and plexuses of the abdominal and pelvic cavities as well as in spinal ganglia.

Degenerative changes also affected nervous cells forming *nucleus intermediomedialis* of the spinal cord These changes were observed in $S_1$ segment (Fig.1) and in one animal - also in neuromer $S_2$. Degenerative cells constituted about 2-3% of all the nerve cells creating this nucleus.

In the spinal cord, individual, changed cells were present in *nucleus intermediolateralis* in $L_1$ to $L_2$ neuromers (Fig.2). Most changes affected the central group of the nucleus described, in the small, oval cells.

The presence of degenerated cells was confirmed in *medulla oblongata*, in *nucleus parasympathicus nervi vagi*. Individual, retrograde cells were observed in this nucleus on the level of *obex* and in the small frontal region of it. Retrograde changes occurred in the nervous cells on both sides of the nucleus.

In all experimental animals, in the ganglia of the sympathetic trunk, retrograde changes were visible on both sides in the ganglia of $L_1$ to $L_5$. In one animal, there occurred changes in the left side ganglion $L_6$ of the sympathetic trunk. In the ganglia described, the changes affected 5 to 10 % of all ganglionic neurons.

Retrograde lesions in 3 experimental dogs were also spotted in the cells of the abdomino-pelvic part of the peripheral autonomic nervous system (Fig.3). The changes were observed in the cells of the coeliac ganglion (1 to 3% of all nervous cells), the

caudal mesenteric (about 5%) and also in some small ganglions of the hypogastric (Fig.4) and pelvic plexuses (about 5 to 15 % of all nervous cells). There occurred only small differences in quantitative intensification of these changes in the examined animals.

Degenerated cells also occurred in all spinal ganglia from $Th_9$ to $S_2$, but the greatest intensification of the retrograde changes was observed in $L_1$-$L_4$ ganglia (3-5% of all ganglionic cells). Small differences in the intensification and placement were noticed in the spinal ganglia. In other spinal ganglia ($Th_9$-$Th_{13}$, $L_5$-$S_2$) only individual degenerated cells were spotted.

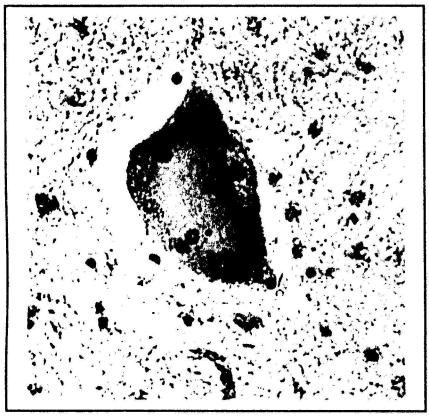

**Fig.1.** Degenerated nerve cells in the *nucleus intermediomedialis* from $S_1$ segment of the spinal cord.

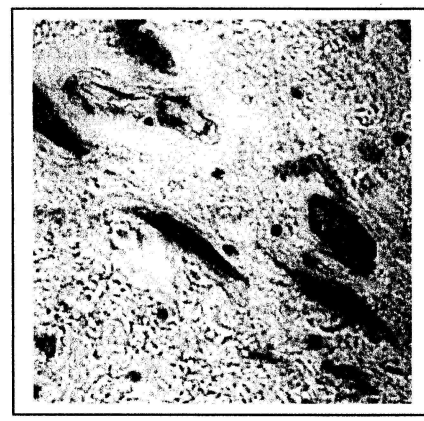

**Fig.2.** Degenerated nerve cells in the *nucleus intermediolateralis* from $L_1$ segment of the spinal cord.

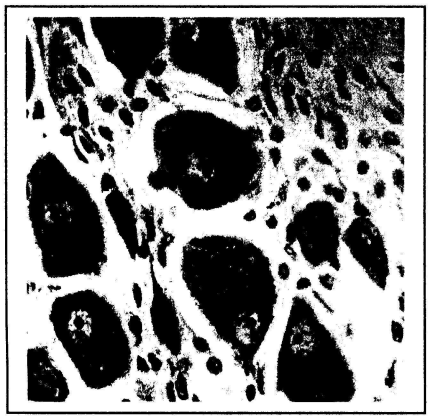

**Fig.3.** Degenerated nerve cells in the *ganglion mesentericum caudale.*

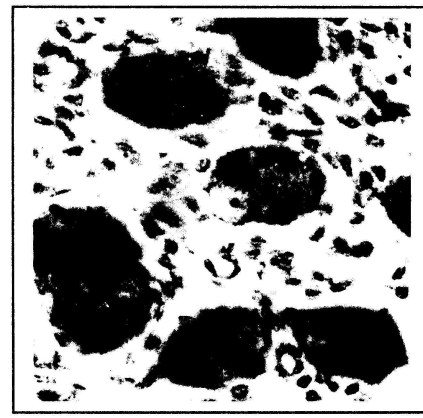

**Fig.4.** Degenerated nerve cells in the ganglion from the *plexus hypogastricus.*

Fig 5. SCHEMATIC REPRESENTATION OF THE SOURCES OF THE AUTONOMIC AND AFFERENT FIBRES TO THE UTERINE CERVIX IN DOGS

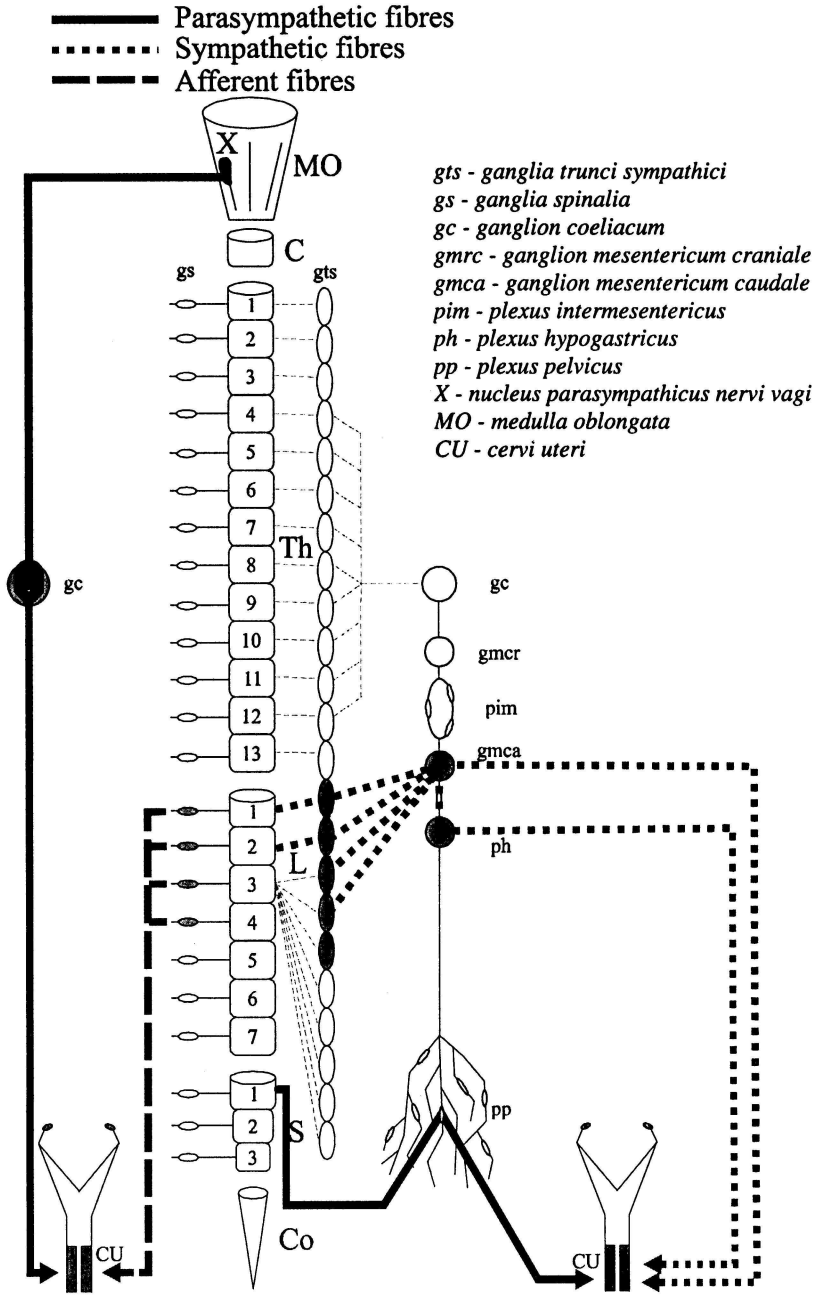

The incision of the abdominal wall in the control animal caused retrograde changes in the nervous cells of spinal ganglia. A small quantity (1-2%) of degenerated cells was observed in all spinal ganglia from $Th_9$ to $S_2$. There were no changes, either in the spinal cord or in the thoraco-abdomino-pelvic part of the peripheral autonomic nervous system.

All degenerated nerve cells were characterised by the advanced tigrolysis, excentrically localized cell nucleus and the cell oedema which triggered a change in the cell shape to more oval or circular. A greater number of glia cells around the degenerated cells was noticed in some peripheral, vegetative ganglia.

## Discussion

As was mentioned earlier, the operational procedures conducted in the study, caused retrograde changes in the nervous cells of the experimental animals both in the central as well as in the peripheral nervous systems. The comparison of the changes in the experimental and control animals provided the reason for localization of nerve cells being the source of origin of the nerve supplying the uterine cervix in female dogs (Fig.5).

The experiments showed that the cells of *nucleus intermediolateralis* from $L_1$ to $L_2$ neuromers of the spinal cord, constitute only a small part of the preganglionic sympathetic nerve fibres supplying the uterine cervix in dogs. The main mass of the sympathetic nerve fibres supplying the organ comes from the nerve cells of the peripheral nervous system. Their source is constituted by the ganglia of the sympathetic trunk from $L_1$ to $L_5$, caudal mesenteric ganglion and also the ganglia dispersed in the region of hypogastric and pelvic plexuses. A similar view on the localization of nerve centres for the uterine cervix in pigs was expressed by Boratyński *et al.* (6) and other authors (9,13,14,15,19). Gloor (18) and Serghini *et al.* (28) point out the particular role played by the paracervical ganglia in the innervation of uterine cervix. They also claim (18,28) that the fibres innervating the organ descend from the ganglia in the suprarenal plexus either through the caudal mesenteric ganglion or through the ovarian plexus. They express the opinion that the fibres supplying the uterus cervix are "non-noradrenergic".

Independently from the views presented above, one should conclude that the ganglia and plexuses discussed may play dual functions. They may be the site of transference of preganglionic fibres (by the means of synapses) and may play the function of the independent neuronal centres (modulatory centres). In the light of Elbadawi *et al.* (11,12) experiments, this seems to be quite probable. Dail (9), nevertheless, says that the modulatory processes on the level of peripheral autonomic ganglia are not very well known yet.

The results of the experiments conducted in this study suggest that parasympathetic fibres for the uterine cervix originate both from the neurons creating *nucleus parasympathicus nervi vagi* in *medulla oblongata* and from the cells of *nucleus intermediomedialis* in segment $S_1$ ($S_2$ in one experimental animal) of the spinal cord. This view is also shared by other authors (4,5,23). A direct proof for the origin and participation of parasympathetic fibres in innervation of the uterine cervix was supplied by Ortega-Villabois *et al.*(27). Using the HRP method, they confirmed the existence of marked cells in *ganglion nodosum* and bilaterally in *nucleus parasympathicus nervi vagi*. Ghoshal and Getty (16,17) concluded that the preganglionic parasympathetic nerve fibres (from *medulla oblongata*) after crossing *ganglion coeliacum* and *plexus*

*intermesentericus* reach the hypogastric and pelvic plexuses and innervate *uterus* as postganglionic fibres. This appears to be also confirmed by Sugitani *et al.*(30) who introduced a marker to the coeliac ganglion and confirmed its presence in *nucleus parasympathicus nervi vagi*, too. It seems, then, that the preganglionic parasympathetic vagal nerve fibres have their synapses in the ganglia of the coeliac plexus. Moreover, in the context of the innervation routes discussed here, one should also consider a very interesting hypothesis (8) concerning „non-equivalent" left and right vagus nerves. Similar transfer is characteristic of preganglionic parasympathetic nerve fibres from *nucleus intermediomedialis* in the sacral part of spinal cord, which is consistent with the same research (4,20,31).

Taking into account the literature data (10,13,14,15,25) and the experiments conducted in this study, one may conclude that the afferent fibres innervating the uterine cervix in dogs originate predominantly from the nerve cells in the lumbar or lumbosacral spinal ganglia. Similar results were obtained by Flieger *et al.*(14). They seem only slightly different from other results (22). The viscerosensory fibres may transmit centripetal impulses by two routes: by the pelvic plexus, and the sacral part of the spinal cord (4,31) or according to the suggestion of other authors (5,10,19,25) - by the pelvic and hypogastric plexuses, hypogastric nerves and caudal mesenteric ganglion.

## References


1. Adham N., Schenk E.A.: Am. J. Obstet. Gynecol. 104, 508, 1969.
2. Baljet B., Drukker J.: Acta Anat. 111, 222, 1981.
3. Bettzieche H.: Zbl. Gynäkol. 96, 560, 1974.
4. Baron R., Jänig W.: J. Auton. Nerv. Syst. 24, 81, 1988.
5. Berthoud H.R., Powley T.L.: J. Auton. Nerv. Syst. 42, 153, 1993.
6. Boratyński Z., Flieger S., Welento J., Krzyżanowski J., Sławomirski J.: Folia Morphol. (Warsz.), 47, 71, 1988.
7. Boratyński Z., Flieger S., Welento J.: Folia Morphol. (Warszawa), 55, 219, 1996.
8. Chavez R., Cruz M.E., Dominguez R.: J. Endocrinol. 113, 397, 1987.
9. Dail W. G.: Microsc. Res. Tech. 35, 95, 1996.
10. DeGroat W.C.: Experientia 43, 801, 1987.
11. Elbadawi A., Schenk E.A.: Z. Zellforsch. 87, 218, 1968.
12. Elbadawi A., Schenk E.A.: Z. Zellforsch. 103, 26, 1970.
13. Flieger S.: Pol. Arch. Wet. 20, 89, 1977.
14. Flieger S., Boratyński Z., Welento J., Eustachiewicz R., Szalak M., Krzyżanowski J., Sławomirski J.: Annales UMCS, s.DD, 34, 35, 1979.
15. Flieger S., Boratyński Z., Welento J., Krzyżanowski J., Sławomirski J.: Folia Morphol. (Warsz.), 47, 77, 1988.
16. Ghoshal N.G., Getty R.: Anat. Anz. 125, 400, 1969.
17. Ghoshal N.G., Getty R.: New Zealand Vet. J. 18, 71, 1970.
18. Gloor H.F.: Experientia, *Supplementum* 19, Birkhäuser Verlag., 1973.
19. Houdeau E., Boyer P.A., Rousseau A., Rousseau J.P.: Cell Tiss. Res. 288, 285, 1997.
20. Kanerva L.: Acta Inst. Anat. (Helsinki), *Supplementum* 2, 1, 1972.
21. Koper S., Welento J., Flieger S.: Medycyna Wet. (Lublin), 30, 231, 1974.
22. Kothbauer O., Schaller D.: Wien. Tierärztl. Mschr. 62, 157, 1975.

23. Langenfeld M., Pastea E.: Anat. Anz. 140, 9, 1976.
24. Massmann G.A., Figueroa J.P., Hoffman G., Nathanielsz P.W.: Biol. Reprod. 46, 483, 1992.
25. Nance D.M., Burns J., Klein C.M., Burden H.W.: Brain Res. Bull. 21, 701, 1988.
26. Nandy K.: Exp. Geront. 7, 303, 1972.
27. Ortega-Villalobos M., Garcia-Bazan M., Solano-Flores L.P., Ninomiya-Alarcon J.G., Guevara-Guzman R., Wayner M.J.: Brain Res. Bull. 25, 365, 1990.
28. Serghini R., Prud'homme M.J., Vaudry H., Rousseau J.P.: J. Auton. Nerv. Syst. 67, 38, 1997.
29. Stiernquist M., Alm P., Ekman R., Owman C., Sjöberg N-O., Sundler F.: Biol. Reprod. 33, 157, 1985.
30. Sugitani A., Yoshida J., Nyhus L.M., Donahue P.E.: J. Auton. Nerv. Syst. 34, 211, 1991.
31. Sullivan K.A., Traurig H.H., Papka R.E.: Anat. Rec. 240, 377, 1994.
32. Wakabayashi K., Takahashi H.: Eur. Neurol. 38, *Supplementum* 2, 2, 1997.
33. Woźniak W., Skowrońska U.: Anat. Anz. 120, 457, 1967.
34. Zintsch I.: Zbl. Vet. Med. 12, 447, 1965.