

## Short note

# *Synhimantus (Dispharynx) nasuta* (Nematoda: Acuariidae) on the Green-barred Woodpecker *Colaptes melanochloros* (Aves: Picidae) in Argentina

Cynthia J. GONZÁLEZ-RIVAS<sup>1</sup>, Gabriel N. CASTILLO<sup>2,3,4</sup>,  
Iván D. SIMONCELLI<sup>1</sup>

<sup>1</sup>Faunístico: Centro de Rehabilitación de Fauna Silvestre, Educación Ambiental y Recreación Responsable, San Juan, Argentina. Ruta Provincial N° 60 km 14 5400 Rivadavia, San Juan, Argentina

<sup>2</sup>Facultad de Ciencias Exactas, Físicas y Naturales, Universidad Nacional de San Juan. Av. Ignacio de la Roza 590, 5402, San Juan, Argentina. Av. Ignacio de la Roza 590, 5402, San Juan, Argentina

<sup>3</sup>Consejo Nacional de Investigaciones Científicas y Técnicas (CONICET). Av. Ignacio de la Roza 590, 5402, San Juan, Argentina

<sup>4</sup>Gabinete de Investigación Diversidad y Biología de Vertebrados del Árido (DIBIOVA). Universidad Nacional de San Juan. Av. Ignacio de la Roza 590, 5402, San Juan, Argentina

Corresponding Author: Gabriel N. Castillo; e-mail: nataliocastillo@gmail.com

**ABSTRACT.** Only a very small percentage of the total bird species reported for Argentina has been studied from the parasitic point of view. This places wild birds as the least studied compared to other vertebrates. In light of this, the goal of the present study is to contribute to the knowledge of endoparasites on wild birds of Argentina. We analyzed a specimen of Green-barred Woodpecker, *Colaptes melanochloros*, which arrived in bad conditions at the Center for Wildlife Rehabilitation, Environmental Education and Responsible Recreation (Faunistic). The bird subsequently died and we proceeded to do a routine postmortem analysis. The analysis determined the presence of four nematodes (3 females and 1 male) of *Synhimantus (Dispharynx) nasuta*, this being the first record for the Green-barred Woodpecker *Colaptes melanochloros* in Argentina. This study provides novel information about parasitism in Argentina's birds.

**Keywords:** birds, faunistic, nematodes, San Juan, parasitism, Rivadavia

### Introduction

Helminthological studies of wild birds are scarce in Argentina, there being just a few records per province [1]. Only 65 out of the 1033 bird species mentioned for Argentina have been reported as being parasitized by adult nematodes [1]. This is a consequence of the collection method, which is biased to only a few wild bird samples available for being analyzed and for conducting studies [2], added to the fact that there are few research groups in Argentina following this line of research [1]. In San Juan province, parasitic studies of wild birds are extremely few [3], this probably being one of the provinces with less records and studies in Argentina. As many as 270 bird species are currently reported for San Juan, distributed among 52 families [4], for

which there is only one record of nematodes on *Rhea tarapacensis* Chubb, 1913 [3].

The nematodes of the genus *Synhimantus (Dispharynx)* Railliet, Henry and Sisoff, 1912 are parasites of the proventriculus and gizzard of many bird taxa, and are characterized by their large pseudolips and modified cuticle structures at the anterior end, which are known as cords [5]. Mainly the species *Synhimantus (Dispharynx) nasuta* Rudolphi, 1819 has health importance because it is pathogenic in birds, and a cosmopolitan species whose distribution encompasses most of the continents [5]. As a general characteristic, the nematode presents a heteroxenous life cycle, whose intermediate host is a terrestrial isopod [6]. In Argentina, there is only one record of *S. nasuta* on *Sturnus vulgaris* Linnæus, 1758, reported for

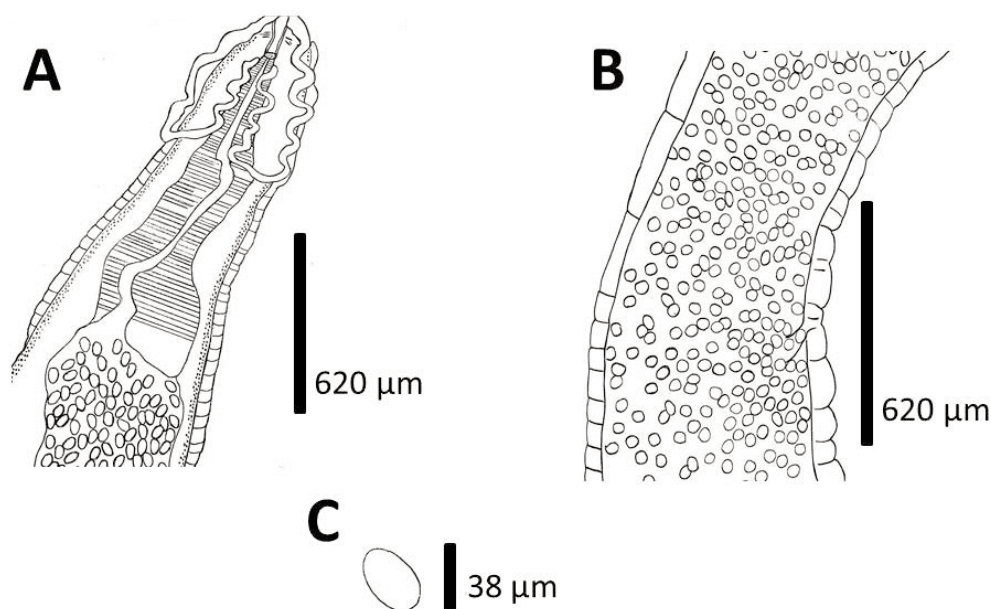


Figure 1. *Synhimantus (Dispharynx) nasuta* pregnant female. (A) Posterior view, cords are observed; (B) View of midbody, showing the vulva; (C) Egg

Buenos Aires province [1–7].

The Green-barred Woodpecker, *Colaptes melanochloros* Gmelin, 1788, is a mid-sized species, (23 cm), and a striking bird due to the distinct red color of its nape [8]. Its distribution stretches from northeast Brazil down to south central Argentina [8]. In Argentina, this species is widely distributed [16], and in San Juan province it occupies a great diversity of habitats, occurring mainly in the Monte region and semiarid Chaco [4]. Its diet is primarily based on insects, with an activity pattern displayed between 09:00 a.m. and 5:00 p.m. [9]. So far, there are no parasitology records of any kind for *C. melanochloros*.

Given the scant knowledge and records of the nematode *S. (Dispharynx) nasuta* parasitizing wild birds in Argentina, the objective of this note is to afford the first record for Argentina of *S. (Dispharynx) nasuta* parasitizing the Green-barred Woodpecker *Colaptes melanochloros*.

## Materials and Methods

In October 2018, a specimen of Green-barred Woodpecker, *Colaptes melanochloros* (Picidae), which came from an urban environment (San Juan city), entered the Center for Wildlife Rehabilitation, Environmental Education and Responsible Recreation (Faunistic), Rivadavia district, San Juan province, Argentina. The bird arrived in a delicate clinical condition, thereby it did not feed and eventually died. The veterinary staff of the Faunistic

Center proceeded to conduct a postmortem examination. During the examination, parasitic nematodes were observed in the gizzard area, which were removed and stored in a 70% ethanol solution. Semi-permanent preparations were made, using lactophenol solution, for observation, identification/determination of the nematodes. Afterwards, for identifying the species that the parasite found belonged to, we used morphological characters, based on [10–12]. The studied nematodes are deposited in the Parasitology Collection of the Center for Wildlife Rehabilitation, Environmental Education and Responsible Recreation (Faunistic) CRFSJ-04A.

## Results

We recorded a total of four adult-stage nematodes (3 females and 1 male) of *Synhimantus (Dispharynx) nasuta* (Figs 1 and 2).

*Synhimantus (Dispharynx) nasuta* Rudolphi, 1819 (Nematoda: Acuariidae)

**General:** Evident sexual dimorphism, with females being larger than males. Robust body, two pseudo lips present, short buccal capsule. Presence of two pairs of anastomosed head cords beginning on the dorsal and ventral sides of the oral opening (in females, it is clearly observed that there is no union of these cords). Esophagus clearly divided into a short anterior muscular part and a long posterior glandular part. In males the caudal wings are poorly developed and with 4 pairs of precloacal

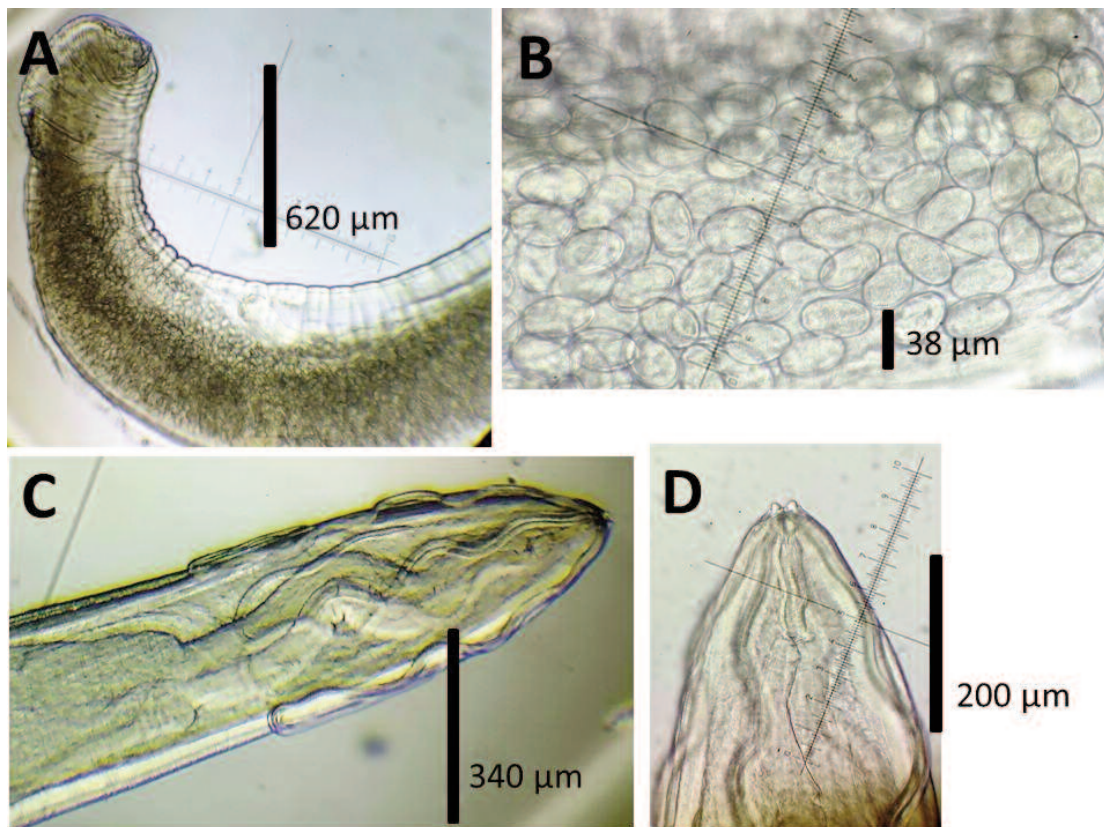


Figure 2. *Synhimantus (Dispharynx) nasuta* pregnant female and male. (A) Female, middle and posterior view; (B) Midbody view, eggs are observed; (C) and (D) Male, anterior view

papillae and 5 pairs of postcloacal papillae. A pair of spicules; the left one thinner and longer; the right is shorter. In females, the vulva is located in the middle of the body.

**Male** (based on 1 specimen) ( $\mu\text{m}$ ): length 4544; maximum width 340.8; cord width 10; muscular esophagus length (short) 98; glandular esophagus length (long) 490; nerve ring 49; excretory pore 1323. Caudal wings present but poorly developed, difficult to see; 18 papillae in total: 4 pairs of precloacal papillae and 5 pairs postcloacal. 2 spicules present.

**Female** (based on 2 specimens) ( $\mu\text{m}$ ): length  $6858 \pm 59.4$  (6816–6900); maximum width  $621.7 \pm 11.74$  (613.4–630); muscular esophagus length (short)  $118.80 \pm 1.7$  (117.6–120); glandular esophagus length (long)  $886 \pm 5.6$  (882–890); cord width  $19.8 \pm 0.28$  (19.6–20); nerve ring  $59.4 \pm 0.85$  (58.8–60). Eggs length  $38.75 \pm 1.7$  (37.5–40), width  $23.25 \pm 1.06$  (22.5–24).

Host: *Colaptes melanochloros* (Gmelin, 1788) (Piciformes, Picidae); (Fig. 3)

Intensity: 4 adult-stage nematodes (3 females and 1 male)

Infection site: Gizzard

Collection site: Urban environment, San Juan city,

Argentina

Deposited material: CRFSJ-04A

## Discussion

The genus *Synhimantus (Dispharynx)* is represented by 23 species that parasitize domestic and wild birds worldwide [13–14]. Out of these, only four species have been reported thus far for Argentina; *Synhimantus milvagoi* Boero and Led, 1971 parasitizing *Phalcoboenus chimango*; *Synhimantus (Dispharynx) nasuta* Chabaud, 1975 infecting the bird *Sturnus vulgaris*, and *Synhimantus (Synhimantus) laticeps* Rudolphi, 1819 as parasite of *Asio clamator* Vieillot, 1807. These three records were collected in Buenos Aires province, and *Synhimantus (Dispharynx) brevicordon* Schuurmans-Stekhoven, 1951 was recorded on the bird *Falco sparverius cinnamominus* Swainson, 1838 in Tucumán province [1]. According to our literature review, there are no parasitological studies for the Green-barred Woodpecker, *C. melanochloros*. This study reports the first record for Argentina of the interaction between *S. (Dispharynx) nasuta* and *C. melanochloros*.

The nematode *S. (Dispharynx) nasuta* is of



Figure 3. Adult specimen of Green-barred Woodpecker, *Colaptes melanochloros* (Photo: Dr. Gustavo Fava)

veterinary importance because it penetrates the gizzard mucosa causing ulcers and an evident inflammation at the point of insertion of the parasite [12]. In our case study, the bird died on the second day after arriving at our Center for Wildlife Rehabilitation (Faunistic) (San Juan province). Although we are not certain about the causes of the animal's death, we do not rule out that parasites might have worsened the clinical picture. Bolette [15] reports parasitism by *Dispharynx nasuta* in the parrot *Polytelis alexandrae* Gould, 1863, the bird's death being attributed to parasitism by this nematode.

Up to now, in San Juan province, there exists only one report for *Rhea tarapacensis* by [3], mentioning the genus *Heterakis* sp. Schrank, very likely corresponding to *Heterakis dispar* Schrank, 1790. The nematode *S. (Dispharynx) nasuta* corresponds to the second parasitological record obtained from a bird in San Juan province.

This research work highlights the importance of the Center for Wildlife Rehabilitation, Environmental Education and Responsible Recreation (Faunistic), in San Juan province, as an institution for scientific studies related to parasitology.

### Acknowledgements

We thank authorities and intendente of the Municipality of Rivadavia, San Juan province. We also thank Faunístico: Wildlife Rehabilitation, Environmental Education and Responsible Recreation Center. Nelida Horak assisted us in drafting the English version.

### References

- [1] Drago F.B., Núñez V., Díaz M.D. 2020. Checklist of the nematode parasites of wild birds of Argentina. *Revue Suisse de Zoologie* 127(1): 43–61. doi:10.35929/RSZ.0005
- [2] Wobeser G.A. 2008. Parasitism: costs and effects. In: Parasitic diseases of wild birds. (Eds. T. Carter, N.J. Atkinson, H.T.D. Bruce). John Wiley and Sons, Inc New Jersey: 3–9.
- [3] González-Rivas C.J., Castillo G.N., Borghi C.E. 2018. Registro de endoparásito en suri cordillerano *Rhea tarapacensis* (Rheiformes: Rheidae) de la precordillera central de Argentina [Record of endoparasites of *Rhea tarapacensis* (Chubb, 1913) (Rheiformes: Rheidae) in the Center Andean foothills in Argentina]. *Neotropical Helminthology* 12(1): 41–46 (in Spanish with summary in English).

- [4] Ortiz S.G., Blanco-Fager R.V., Gómez H.A., Videla L.B., Godoy-Luna E. 2016. Aves de las diferentes ecorregiones, San Juan, Argentina. In: San Juan Ambiental. (Eds. E. Martínez-Carretero, A. García). Inca Editorial, 1º ed. Mendoza, Argentina: 259–276 (in Spanish).
- [5] Carreno R.A. 2008. *Dispharynx*, *Echinuria*, and *Streptocara*. In: Parasitic diseases of wild birds. (Eds. T. Atkinson, J.N. Thomas, D.B. Hunter). Wiley-Blackwell, Iowa, USA: 326–341.
- [6] Anderson R.C., Chabaud A.G., Willmott S. 2009. Keys to the nematode parasites of vertebrates. Wallingford, CAB International.
- [7] Valente R., Ibañez L.M., Lorenti E., Fiorini V.D., Montalti D., Diaz J.I. 2014. Helminth parasites of the European starling (*Sturnus vulgaris*) (Aves, Sturnidae), an invasive bird in Argentina. *Parasitology Research* 113: 2719–2724. doi:10.1007/s00436-014-3928-3
- [8] Narosky T., Yzurieta D. 2003. Guía de identificación de las aves de Argentina y Uruguay. Vazquez Mazzini Editores (in Spanish).
- [9] Beltzer A.H., de Amsler G.P., Neffen M.I. 1995. Biología alimentaria del carpintero real *Colaptes melanochloros* (Aves: Picidae) en el valle aluvial del río Paraná, Argentina. *Anales de Biología* 20: 53–59 (in Spanish).
- [10] Sahay U. 1966. On *Dispharynx nasuta* Rudolphi, 1819 (Acuariidae Seurat, 1919, Railliet, Henry et Sisoff, 1912) from an Indian bird *Megalaima asiatica* (Latham). *Japanese Journal of Medical Science and Biology* 19(3): 147–153. doi:10.7883/yoken1952.19.147
- [11] Al-Moussawi A.A. 2016. The nematode *Dispharynx nasuta* in the white-cheeked bulbul *Pycnonotus leucogenys* in Baghdad city, central Iraq. *Journal of Entomology and Zoology Studies* 4(2): 422–424.
- [12] Oyarzún-Ruiz P., Muñoz-Alvarado P., Raffo, E. 2016. Helminths of (Aves: Falconiformes) from Los Ríos Region, Chile: new records for Neotropical raptors. *Helminthologia* 53(4): 336–353. doi:10.1515/helmin-2016-0037
- [13] Skrjabin K.I. 1916. Nematodes des oiseaux du Turkestan russe. *Annuaire du Musee Zoologique de l'Academie Imperiale des Sciences* 20: 457–557.
- [14] Zhang L., Brooks D.R., Causey D. 2004. Two species of *Synhimantus (Dispharynx)* Railliet, Henry and Sisoff, 1912 (Nematoda: Acuarioidea: Acuariidae), in passerine birds from the Area de Conservacion Guanacaste, Costa Rica. *Journal of Parasitology* 90(5): 1133–1138. doi:10.1645/ge-3253
- [15] Bolette D.P. 1998. Dispharynxiasis in a captive princess parrot. *Journal of Wildlife Diseases* 34(2): 390–391. doi:10.7589/0090-3558-34.2.390
- [16] Roesler I., Giusti M.E. 2021. Aves. In: Inventario biológico argentino: vertebrados. (Eds. V. Bauni, C. Bertonatti, A. Giacchino). 1st ed. Ciudad Autónoma de Buenos Aires: Fundación de Historia Natural (in Spanish).

Received 09 June 2022

Accepted 23 August 2022