

Technical aspects of prosthetically guided maxillofacial surgery of the mandible. A pilot test study

LEONARDO CIOCCA^{1*}, SIMONA MAZZONI², CLAUDIO MARCHETTI², ROBERTO SCOTTI¹

¹ Section of Prosthodontics, Department of Oral Science, Alma Mater Studiorum University of Bologna, Italy.

² Maxillo-facial Surgery Unit, Faculty of Medicine, Alma Mater Studiorum University of Bologna, Italy.

A test of the accuracy in transferring the virtual data into the surgical environment was carried out. Differences between the virtually planned and the actual position during surgery of the rapid prototyped guides and the bone plates were investigated. The accuracy of the method was evaluated in terms of the precision of cuts in the mandible, the final positions of the rami and condyles, and the sectioning precision of the fibula. The guide position presented a mean value dislocation of 0.6 mm in the right side and of 4.1 mm in the left side; the cut line of the mandible presented an angular deviation of 2.9° (right) and of 17.5° (left). The right condyle was positioned 2.5 ± 0.05 mm more medial than native position, and the left condyle 5.2 ± 0.05 mm medial. The total length was 0.3 ± 0.05 mm short of the virtually projected length at the inferior margin of the mandible and 1.9 ± 0.05 mm longer than projected at the superior margin. The Prosthetically Guided Maxillofacial Surgery (PGMS) is a viable way to improve the precision of mandibular reconstruction using a fibula free flap.

Key words: bone plate, CAD-CAM, maxillofacial prosthesis

1. Introduction

The reconstruction of mandibular defects represents a challenge in head and neck reconstructive surgery after oncologic resection. Currently, microvascular free flap reconstruction remains the first choice. The fibula free flap, first introduced by Hidalgo in 1989, is used routinely, and iliac-crest free flaps or soft-tissue flaps with subsequent bone grafts are second choices [1].

Computer-aided design/computer-aided manufacturing (CAD/CAM) and rapid prototyping (RP), introduced in the last decade, can now help the surgeon to improve the precision of mandibular reconstruction. The indirect CAD/CAM method enables the printing of computed tomographic (CT) data to produce a three-dimensional (3D) stereolithographic

model of the mandible (biomodel), on which the plate can be manually shaped preoperatively. Although this method is currently used widely and reduces operating time, shaping precision is limited by at least three factors: (1) bone deformities are printed together with healthy bone, (2) the elastic properties of the manually bent titanium plate can cause positioning bias, and (3) positioning of the manually bent plate is not guided during the operative procedure. To improve this situation, in this study we evaluated the accuracy of a direct CAD/CAM system and additive manufacturing technologies in mandibular reconstruction by describing a case sample as a pilot test study.

Background

Several articles have evaluated the ability of CAD/CAM systems to meet the clinical demands of

* Corresponding author: Leonardo Ciocca, Via S. Vitale 59, 40125 Bologna Italy. Fax: +39 051 225208, e-mail: leonardo.ciocca@unibo.it

Received: February 22nd, 2013

Accepted for publication: November 13th, 2013

maxillofacial surgery. Scolozzi et al. [2] compared the accuracy and reliability of post-traumatic orbital volume restoration performed with not-preformed mesh plates or 3D preformed titanium mesh plates. They found no significant difference in the use of a conventional or guided CAD/CAM protocol for orbital volume restoration. Chen et al. [3] evaluated the accuracy of the use of a CT-based osteotomy template in intraoral vertical ramus osteotomy (IVRO) to correct mandibular prognathism in cadaveric mandibles. They concluded that the system was convenient and increased intraoperative accuracy and efficiency in IVRO. Ibrahim et al. [4] analyzed the capacity of selective laser sintering (SLS), three-dimensional printing (3DP), and PolyJet models to reproduce mandibular anatomy and their dimensional error. They concluded that the SLS prototype showed greater dimensional accuracy than did the PolyJet and 3DP models, and that the PolyJet technique reproduced anatomic details of the mandible more accurately. Antony et al. [5] investigated the technical accuracy, esthetic contours, and functional outcomes of virtual surgical planning and stereolithographic modeling, finding that this technology facilitated the realization of these parameters. Weitz et al. [6] evaluated the accuracy of implant placement aided by an RP surgical template that was produced using a DICOM-format dataset from a Sirona Galileos cone-beam CT system. They found that the dataset showed low accuracy and a high degree of deviation, and thus was unable to provide accurate surgical transfer in implant surgery. Kim et al. [7] investigated the production and accuracy of digitally printed wafers to induce maxillary movement during bimaxillary orthognathic surgery. They concluded that the RP interocclusal wafer produced with the aid of digitally modeled surgery was an appropriate alternative for maxillary orthognathic surgery. Ciocca et al. [8]–[10] examined prosthetically guided maxillofacial surgery (PGMS), describing examples of the use of custom-made surgical guides for mandibular sectioning and the laser printing of a custom-made titanium bone plate to support the free fibula flap according to esthetic and functional demands.

However, to our knowledge, no reported study has evaluated the accuracy of PGMS, especially for mandibular wide reconstruction, in which the potential of these new technologies seems to offer new options for simplifying surgical and prosthetic procedures. The aim of the present study was to test the accuracy of custom-made CAD/CAM surgical guides and bone plates in mandibular reconstruction with a vascularized free flap.

2. Methods and materials

Patients

The ethical approval of the University Hospital was obtained before starting the protocol, and the Helsinki declaration guidelines were followed during this investigation. The study was approved by the S. Orsola Hospital Ethical Committee in September 2011 (approval no. 57/2011/O/Disp), and all enrolled patients signed an informed consent form.

A 47-year-old woman was scheduled for the ablation of an ameloblastoma involving a large part of the mandibular body, from the right to the left angles of the rami. The status of the tumor was advanced; it involved the teeth and had destroyed the anterior part of the mandibular alveolus, preventing the use of the patient's native occlusal anatomy to prosthetically guide mandibular reconstruction. For this reason, a dentate mandible was selected from the library and adapted to the dimensions of the patient's occlusion, yielding a virtual model that enabled the reproduction of the patient's native mandibular anatomy before the development of the tumor.

This case was selected for its complexity: it summarizes, as lacking, all the variables involved in PGMS. The first is concerning the width of the defect created by the tumor removal: this is the maximum size (bilateral and angle-to-angle) of defects after ablative surgery; the second variable of PGMS is the simulation of the native mandible: in this case no CT data set of the healthy mandible existed, because the ameloblastoma was late diagnosed when the natural anatomy was yet destroyed; the third variable is the occlusion: in this case non occlusion was available to correctly project the final occlusion for guiding the fibula free flap position, because all teeth were dislocated by the ameloblastoma; the fourth variable is the anatomical face contour to preserve after the surgery: in this case the entire profile was altered by the volume of the tumor, and no data were available for restoring a correct face appearance as before the illness.

Surgical planning

Planning began with a high-resolution CT scan of the patient's craniofacial skeleton and soft tissues. CT imaging was performed using a multi-detector CT scanner (HiSpeed CT scanning station; GE Healthcare, Milwaukee, WI, USA) and volumetric data were acquired (1.25 mm slice thickness, 512×512 pixel resolution). The DICOM-format data were proc-

essed using the CMF software (ver. 6.0; Materialise, Leuven, Belgium). After a suitable threshold value was set, this software allowed the creation of a 3D virtual model of the maxillofacial skeleton in which planning of the surgical cuts was clearly highlighted. Preoperative CT data were also processed using the Mimics software (ver. 14.12; Materialise) to obtain an accurate 3D model for use in the following procedures.

Prosthetically guided CAD

The CAD of the surgical device was provided by the ClayTools system (Freeform Modeling Plus software and Phantom Desktop Haptic device; Sensable, Wilmington, MA, USA). The customized surgical guides for the cuts were designed first. The guide for the mandible was designed in two parts, for the left and right sides. Each part was constructed with two arms (for the inferior margin of the mandibular angle and the anterior margin of the ramus) to allow positioning on the bone as planned and to ensure precise engagement on the residual mandible. When a complete periosteal flap elevation was obtained at the beginning of the surgery, the surgical guides were carefully positioned in the mandibular angle so that the two arms firmly adhered to the bone: firstly the angle arm was positioned in the mandibular angle, then, with a rotational movement, the anterior arm was positioned in place along the body of the mandible. After a precise insertion was obtained, four holes (2.4 mm diameter) were created at the extremities of the guide to allow fixation to the mandible with titanium screws. The guide for the fibula was designed using the vascular peduncle as a reference for its positioning on the bone, taking into account muscle insertion and avoiding interference during guide inseting. The guide presented all planes for orienting the piezoelectric bone cutter and refining the angles of the fibular fragments according to mandibular contours and esthetic appearance. The third component was the customized reconstructive bone plate that supported the fibula free flap.

For reconstructing the continuity of the mandible, a dentate mandible was selected from the library and ideal occlusion was established using a virtual articulator. After virtually determining the ideal position of the dental arch, six implants were virtually positioned in ideal positions for the construction of a Toronto bridge. The fibula was then positioned to allow correct implant positioning in the virtually predetermined positions. Correct anteroposterior spread of the implants may allow the most extended dimension of the cantilever in the grafted position.

Reference notches were created to delimit the part of the guide that was meant to support the fibula free flap. An array of holes (2.4 mm diameter) was created along the plate to allow fixation of the fibula free flap to the plate and the plate to the maxilla and zygoma. The two components were projected so that the position of each was unique when used in sequence (guide first, plate second), and the same four holes were used to fix each component to the maxilla. The positions of the holes were also planned to avoid interference of the titanium screws with the future positions of the dental implants in the fibula. Also, the holes for the fibula-fixing screws were projected in a way that allowed the fibular sections to be perfectly transferred and positioned onto the bone plate. The same holes were made in the cutting guide of the fibula and used to fix the guide during bone cutting. Those holes were the same as in the bone plate, so that the positions of the fibula sections could be guided as virtually predetermined. This feature guaranteed that bone regeneration using the fibula free flap could be guided anatomically, according to the natural appearance of the maxillary bone.

Rapid prototyping

The cutting guide and bone plate were prepared for laser sintering with the Magics software (ver. 16.02; Materialise) and an RP machine (Eosint P100 Formiga; Electro-Optical Systems GmbH, Munich, Germany). The surgical guide was made from polyamide material (certified biocompatible and autoclavable), except the part containing the drill guide for screws, where a CrCo metal embrasure was constructed to prevent erosion of the polyamide during drilling. The bone plate was fabricated using the working principle based on direct metal laser sintering (DMLS), in which metal powder was fused into a solid and melted locally using a focused laser beam. As is typical for additive manufacturing technologies, the parts were built up additively, in layers. The bone plate was produced using EOS titanium Ti64, a pre-alloyed Ti6AlV4 alloy in fine-powder form with excellent mechanical properties and corrosion resistance combined with low specific weight and biocompatibility, which is particularly suitable for the production of biomedical implants. The biomodel of the actual mandible and skull was manufactured directly using the RP machine. The working principle was based on SLS of polyamide powder, as in DMLS. This biomodel allowed the surgeons to conduct preoperative training. Finally, the surgical guide and bone plate were delivered for sterilization.

Surgery

The mandible was accessed through bilateral submandibular/cervicolateral incisions and the tumor was delimited. The cutting guide was introduced into the field and fixed to the mandibular bone, leaving the proposed surgical margins free for cutting. The guides were stabilized in the correct positions using the two arms (posterior and anterior); insertion of the left guide in the ramus was made problematic by the undercut of the anterior arm, although the posterior arm could be positioned correctly at the angular margin of the mandible. This difficulty caused one of the errors detected in the postoperative analysis of the results. The cutting guide was fixed with titanium screws, and a sagittal saw was then used to create the osteotomy. After mandibular resection, the guide was removed. The bone plate was introduced and fixed to the mandible

using the same holes with which the cutting guide had been fixed to assure the correct mutual positioning of the two components.

Comparative analysis

A follow-up CT scan was performed at 2 weeks postoperatively and data were compared with the virtual surgical planning. (Fig. 1) The predictor variables of this pilot test were: 1. Positions of guides and accuracy of cuts in the mandible; 2. Final positions of the rami and condyles; 3. Precision of sectioning of the fibula. All measurements were calculated on the basis of the pre-op CAD design and the post-op CT data: the difference between these values described how much was accurate the transfer of virtual data into the surgical environment.

The first step was to compare pre- and postoperative skull alignment. (Fig. 2) Alignment of the

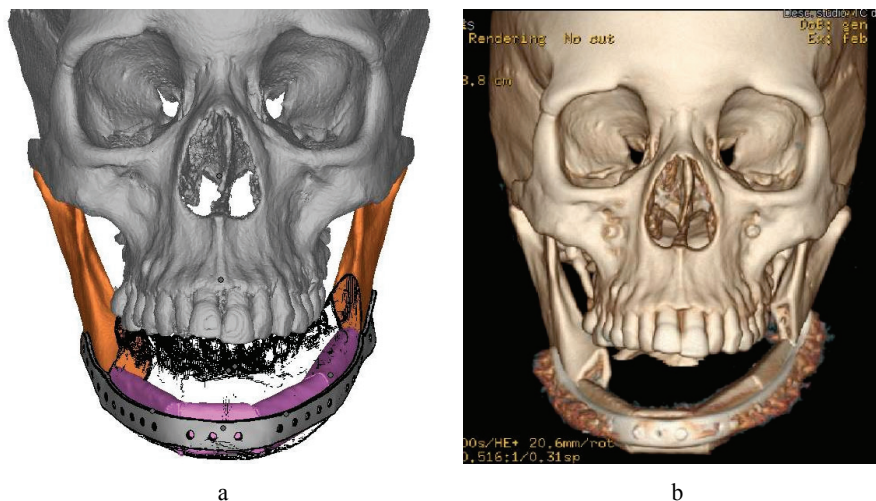


Fig. 1. Computer-aided design project and postoperative computed tomographic data.
Note that the left ramus of the mandible is inclined medially

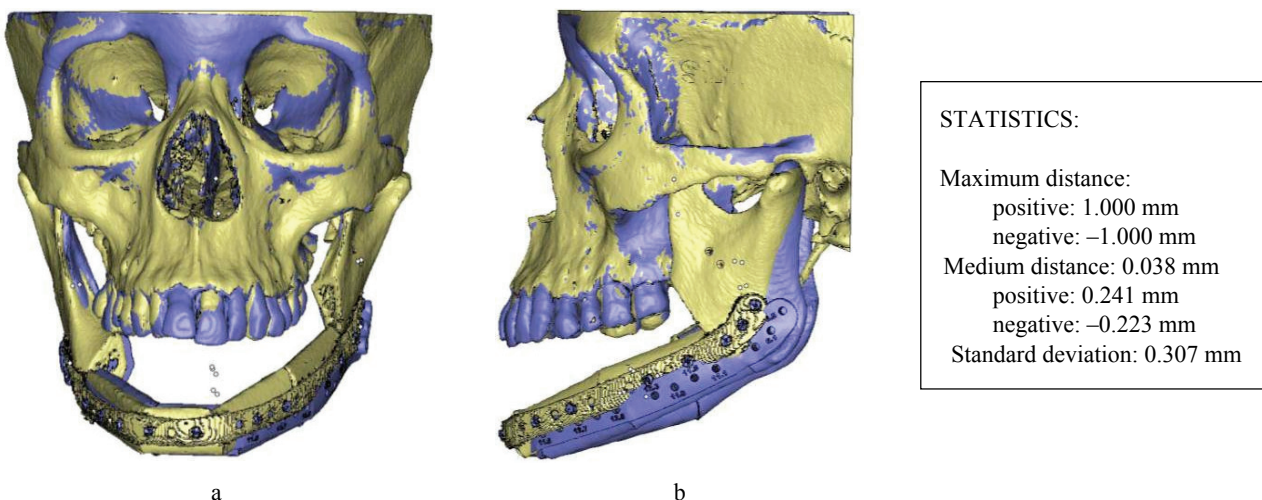


Fig. 2. Projected (blue) and actual (yellow) bony reconstruction: accuracy evaluation

two skulls was carried out using the 3-Matic software (ver. 6.1; Materialise). To verify correct alignment, distances between the same anatomic points (cranial and maxillary surfaces) were measured on both CT data sets, and differences in tolerance and resolution were determined to not significantly affect the measurements. For guide repositioning, the holes in the mandibular ramus were used as landmarks to superimpose the holes in the guides. The center point among holes in the postoperative ramus was determined; from this point, a circumference with the same diameter as the guide holes was designed, and the guides were repositioned on the ramus using these holes, which were the same in the bone and the guides. The same procedure was applied to the bone plate, enabling comparison of the virtual design with the actual implanted bone plate. This measure may contain a bias due to the modality of comparison: the bone plate in the design is not loaded like that extracted from the CT scan, that is, functioning and under the action of the muscles and biomechanical loading. Thus, the imprecision of the values may be due to physiologic masticatory loading and not to any supposed prototyping error.

After a precise alignment was obtained, the second step of measurements began. In the mandible, all components of the analysis (mandibular rami, bone plate, fibula sections) were isolated. Differences between the projected and actual positions were calculated (mean, 0.1 ± 0.05 mm).

The third step was the calculation of the error in guide positioning. (Fig. 3) The unique possibility to calculate the position of the guide using postoperative CT data was to determine the position of the guide at the moment of cutting using the holes for the fixing screws. Those holes were clearly visible on postoperative CT images and were readily superimposed with the preoperative design of the guides by matching the holes in the guides and the bone. In this way, the exact position of the guide at the moment of surgical cutting was visualized and positional differences were calculated.

3. Results

Three elements were evaluated to assess the critical aspects of the accuracy of the system: the positions of the guides and the consequent precision of the cuts in the mandible, the final positions of the rami and condyles, and the sectioning of the fibula.

3.1. Positions of guides and accuracy of cuts in the mandible

- Positions of the guides. Right guide (Fig. 4b): the differences in the center positions of the three holes were 0.5 ± 0.05 , 0.6 ± 0.05 , and 0.6 ± 0.05 mm, respectively, from posterior to anterior. Left guide (Fig. 4a): the differences were 3.1 ± 0.05 , 4.1 ± 0.05 , and 5.3 ± 0.05 mm from the posterior to anterior hole.
- Precision of the bone cuts: Right ramus the bone cut line presented an angular deviation of $2.9 \pm 0.05^\circ$, with a linear error of 0 mm excess at the inferior margin and 0.9 ± 0.05 mm at the superior margin. Left ramus (Fig. 5a, b): the bone cut line presented an angular deviation of $17.5 \pm 0.05^\circ$, with a linear error of 5.4 ± 0.05 mm excess at the inferior margin and 5.4 ± 0.05 mm at the superior margin.

3.2. Final positions of the rami and condyles

The right condyle was positioned 2.5 ± 0.05 mm medial of its preoperative position, with a 3.117 mm medial deviation of the ramus at the inferior extremity of the stump; the coronoid apophysis also deviated 2.1 ± 0.05 mm medially. The left condyle was positioned 5.2 ± 0.05 mm medial of its preoperative position, with a 3.0 ± 0.05 mm medial deviation of the ramus at the inferior extremity of the left stump; the coronoid apophysis also deviated 2.0 ± 0.05 mm medially.

3.3. Sectioning of the fibula

Results regarding the accuracy of fibula sectioning are presented in Table 1. The total length was 0.3 ± 0.05 mm short of the virtually projected length at the inferior margin and 1.9 ± 0.05 mm longer than projected at the superior margin. Differences between projected and actual dimensions of single units seemed to be higher than the mean value, but when taken together the fibula units resulted in nearly complete dimensional precision compared with the virtual model. However, the main alteration in fibula sectioning may be detected by examining the positions of the single units. In the sample case presented here, no variation was detected.

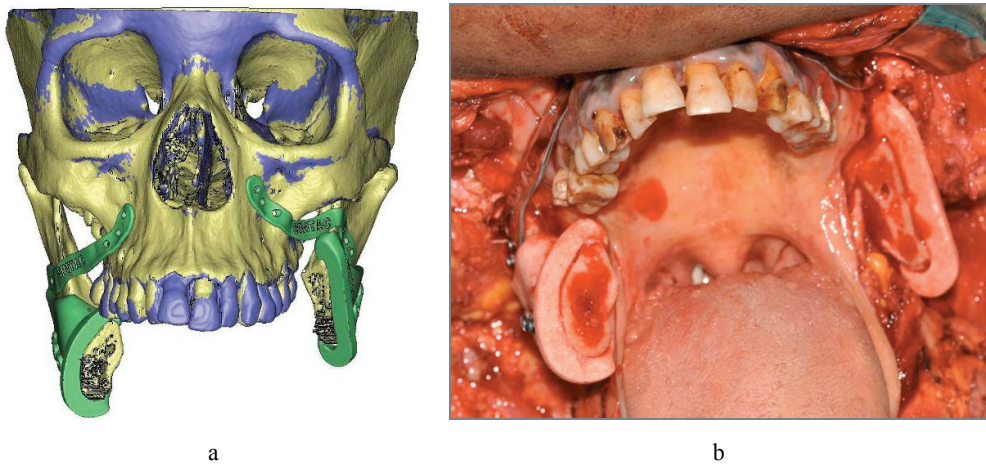


Fig. 3. Origin of the error: (a) malpositioning of the surgical guide before bone cutting. Note the ectopic position (green) of the custom made Luhr plates; (b) the clinical error in positioning the Luhr plates without flap elevation in the maxilla

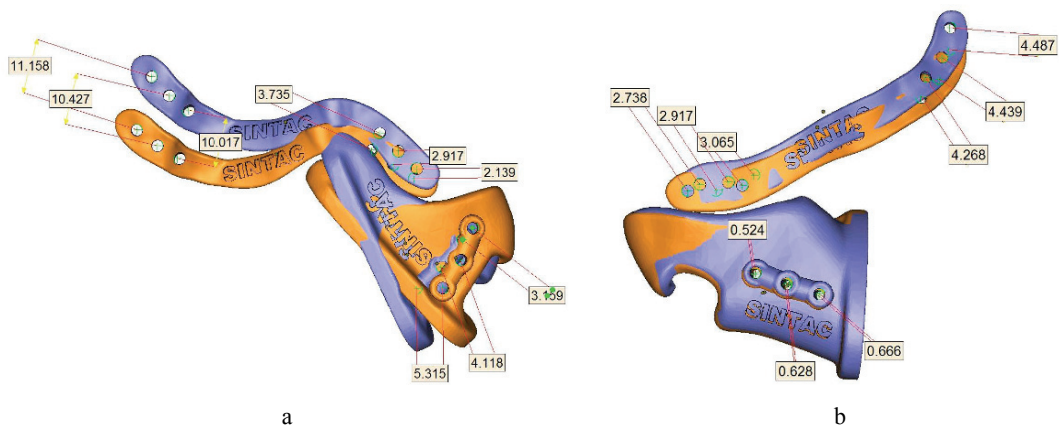


Fig. 4. Measurements of errors in surgical guide positioning: (a) left guide and Luhr plate, (b) right guide and Luhr plate

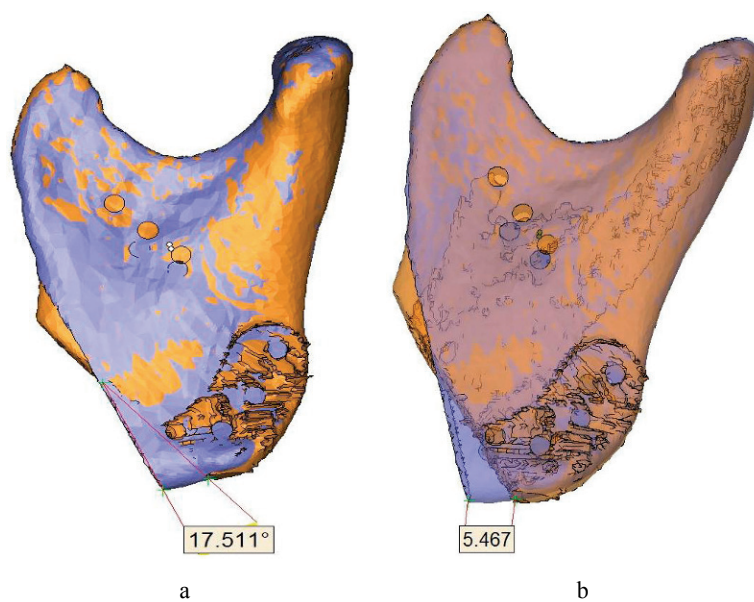


Fig. 5. Anatomic consequences of guide malpositioning: (a) angular variation, (b) linear variation

Table 1. Measurements of dimensional variations in the fibula units: pre- vs. postoperative

FIBULA UNIT (from left angle)	Bottom length*	Top length*	Diameter*
1 PROJECT	41.1	35.6	13.1
POSTOPERATIVE	39.0	36.1	11.1
Difference	-2.1	+0.4	-2.0
2 PROJECT	30.8	33.2	13.8
POSTOPERATIVE	33.0	33.8	12.0
Difference	+2.2	+0.6	-1.8
3 PROJECT	21.6	17.9	14.8
POSTOPERATIVE	22.0	16.8	13.5
Difference	+0.3	-1.0	-1.2
4 PROJECT	45.2	41.6	14.4
POSTOPERATIVE	44.4	43.4	13.6
Difference	-0.8	+1.8	+0.7
TOTAL length difference (mean)	<u>-0.3</u>	<u>+1.9</u>	

* All measurements are expressed in mm and are intended ± 0.05 mm.

4. Discussion

Several papers have documented the successful use of the fibula free flap, especially in mandibular reconstruction. Oromandibular reconstruction after cancer removal using a vascularized fibula free flap is currently a standard treatment option [11]–[12]. Primary reconstruction offers the best opportunity to achieve optimal esthetic and functional results [13]. The use of vascularized bone tissue in secondary reconstruction permits superior restoration of articulation, deglutition, and mastication, esthetic improvement of facial appearance, and improvement of the patient’s quality of life in comparison with the use of non-vascularized alternatives [14]. However, a prosthetic challenge remains: the position of the fibula often makes prosthetic rehabilitation very difficult, due to the lack of interocclusal relationships when reconstructing the bony contour. For this reason, the maxillofacial surgeon wants a system that facilitates the demolition phase and the correct positioning of the fibula. CAD/CAM procedures and modern RP technology offer new possibilities for increasing precision and saving intraoperative time. However, accurate preoperative training of the surgeon is required to ensure the best use of such procedures, especially in the restoration of a complex clinical case, as in the example presented here. The critical aspects carried out in this pilot test case may be useful for the correct application of the PGMS protocol by the surgeon.

A critical aspect involves the initial phase of guide positioning. A guide with severe undercuts may be difficult to position on the bone, and flap residuals

may interfere with the perfect adhesion of the guides to the external surface of a bone that is not completely free of periosteum. Both problems were present in the pilot test case presented here, resulting in displaced positioning of the left guide. In contrast, the right guide fitted well on the ramus and little deviation was observed; the cut line was altered by no more than 0.6 ± 0.05 mm. Because the holes for the guide-fixing screws are the same as those in the bone plate, this positioning error resulted in the incorrect positioning of the entire reconstruction for two main reasons: the medial and frontal rotation of the left stump of the mandible, and bending of the reconstructive plate resulting in a lateral deviation of the neomandible to the right.

The cut line was significantly altered on the left side: the diverse inclination of the cut determined a 5.4 ± 0.05 mm linear error at the inferior border of the left stump. After altering the locations of the fixing screws and the cut lines, the surgeon could only position the fibula according to these errors. Moreover, because the positions of the holes for the fixing screws deviated more on the left than on the right side and the two altered positions (left and right) were not related or proportional to each other, the reconstructive bone plate was forced to adapt to these problems, causing medial and frontal rotation of the left ramus and lateral deviation of the inferior neomandibular midline to the right.

As a result, analysis of the variation in bone plate morphology (Fig. 6) between the virtual project and the postoperative CT data revealed two main points of deviation: at the right connection with the right mandibular stump, and in the left canine zone. However, no conclusion can be drawn from this comparison because

the discrepancy does not clarify whether a prototyping error occurred or the deviation was due to the functional loading of the reconstructive bone plate. If the accuracy of 3DP can be registered, a virtual project should be compared with a prototyped volume before surgical inseting.




Fig. 6. Computerized calculation of variation in the volume of the bone plate: the preoperative design was compared with the bone plate “in function” using a postoperative computed tomographic data set. The maximum difference was in the right ramus screw connection (in the figure the upper part in yellow-red) and in correspondence of the first fibula unit on the left mandible (in the figure the lower yellow part). Note that the bone plate is overturned toward the bottom

The second critical aspect of PGMS is the anatomic deviation of the condyle due to the previous guide positioning errors. These errors resulted in a deviation of the left ramus after bony reconstruction with the fibula free flap. A lateral dislocation (5.2 ± 0.05 mm) of the left condyle was detected, and the inclination of the left ramus deviated 8.779° in the lateral plane (Fig. 7a). The right ramus also presented a 2.5 ± 0.05 mm lateral malposition and an angular deviation of $2.1 \pm 0.05^\circ$. Even with these discrepancies between the pre- and postoperative anatomic positions of the mandibular rami, no interference with functional movement of the temporomandibular joint was detected: opening, protrusive, and lateral movements of the reconstructed mandible showed no limitation during 4 months of follow-up after surgery.

At least one more critical aspect of PGMS is fibula sectioning. Three main problems may be encountered when applying the cutting guide to the fibula: precise fitting on the cortical bone without the interference of flap residuals or peduncle, the difficulty of inserting the bone saw or ultrasonic instrument into the guide, and refining of the angles of the fibula units. As in the mandible, the initial fitting of the guide is fundamental for the precise reproduction of the projected cut lines in the surgical environment. Because the fibula is a long bone with similar central anatomy, the guide

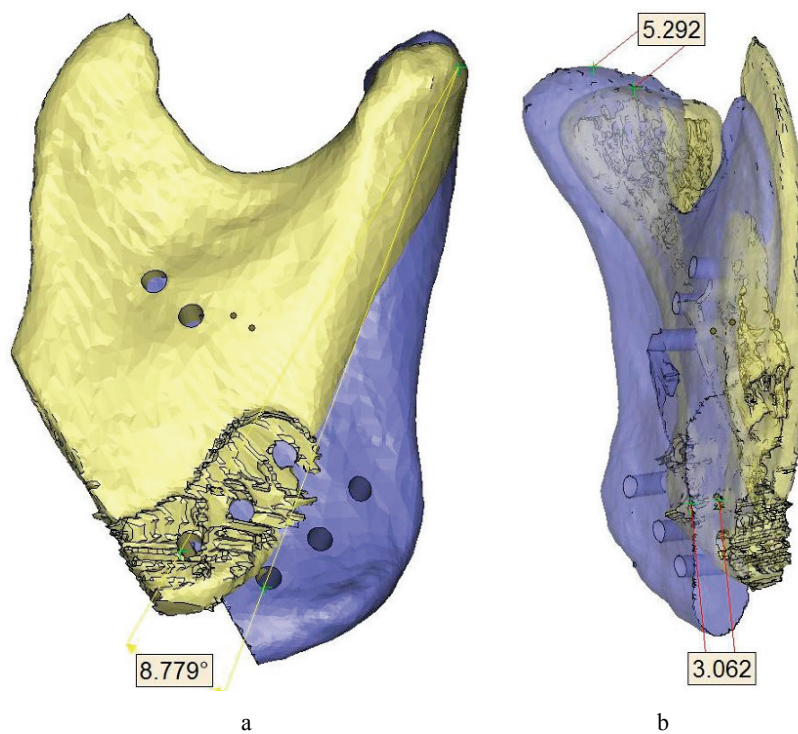


Fig. 7. Inclination (a) and lateral malpositioning (b) of the left ramus (preoperative, blue; postoperative, yellow)

may be erroneously positioned distal or proximal of the planned location due to a longitudinal shift along the fibula. A sufficient design for the precise insertion of the guide can address this issue, but inseting on the fibula may be problematic if any residual tissue remains on the supporting surface of the bone. Thus, guide projection must be carried out with the surgeon to best program the flap design and the access path to the fibula. The guide is projected for an oscillating bone saw, with slots that should guide its inclination and the depth and width of the fibula. When the use of an ultrasonic bone cutting device is necessary, insertion into the slot is difficult and sometimes prevents penetration of the entire volume of the fibula. For this reason, it is essential to know what device will be used before projecting the guide for the fibula, to program the best slot dimension: the slot must guarantee the best orientation and deeper insertion of the bone cutting device, while preventing the device dimensions from interfering with the guide. Refining the angles of the fibula units to better accomplish final inseting in the bone plate can sometimes be problematic due to the inclination of the surgical cut lines reproduced in the guide planes. As in the case described here, major difficulty may be encountered in inserting the cutting device into the slots. Moreover, a secondary difficulty may be encountered in the removal of the thin layer of bone; only a small chamfer should be created on some fibula units, and a bone cutter cannot section such a thin layer of bone. In this case, the fibula guide should be removed and the fibula refined manually.

Precision in guide positioning and in the consequent bone sectioning, possible distortion of the metal plate under functional loading, anatomic deviation of the condyles, and precise fitting of the fibula surgical guide, are very important factors influencing the accuracy of the Prosthetically Guided Maxillofacial Surgery.

However, training of the surgeon on resin models is necessary before surgery to avoid all possible critical aspects of PGMS that can prejudice a favorable outcome with this new CAD/CAM technique. During surgery, greater precision in reproducing all phases of the procedure (in particular, the inseting of the cutting guides and the osteotomies of the mandibular/fibular bone) is important to achieve the desired, virtually projected results.

Acknowledgment

The authors thank Dr. Andrea Sandi (Sintac, Rovereto, Italy) for his valuable work in designing and in the rapid prototyping of the surgical guide and bone plate.

References

- [1] MARCHETTI C., BIANCHI A., MAZZONI S., CIPRIANO C., CAMPOBASSI A., *Oromandibular reconstruction using a fibula osteocutaneous free flap: four different preplating techniques*, *Plast. Reconstr. Surg.*, 2006, 118, 643–651.
- [2] SCOLOZZI P., MOMJIAN A., HEUBERGER J., *Computer-aided volumetric comparison of reconstructed orbits for blow-out fractures with nonpreformed versus 3-dimensionally preformed titanium mesh plates: a preliminary study*, *J. Comput. Assist. Tomogr.*, 2010 Jan., 34(1), 98–104.
- [3] CHEN X.Y., CHEN S.L., ZHANG X., LI J.P., DENG W., *Accuracy of intraoral vertical ramus osteotomy with a stereolithographic template*, *Ann. Plast. Surg.*, 2011 Jan., 66(1), 88–91.
- [4] IBRAHIM D., BROILO T.L., HEITZ C., DE OLIVEIRA M.G., DE OLIVEIRA H.W., NOBRE S.M., DOS SANTOS FILHO J.H., SILVA D.N., *Dimensional error of selective laser sintering, three-dimensional printing and PolyJet models in the reproduction of mandibular anatomy*, *J. Craniomaxillofac. Surg.*, 2009 Apr., 37(3), 167–73.
- [5] ANTONY A.K., CHEN W.F., KOLOKYTHAS A., WEIMER K.A., COHEN M.N., *Use of virtual surgery and stereolithography-guided osteotomy for mandibular reconstruction with the free fibula*, *Plast. Reconstr. Surg.*, 2011 Nov., 128(5), 1080–1084.
- [6] WEITZ J., DEPPE H., STOPP S., LUETH T., MUELLER S., HOHLWEG-MAJERT B., *Accuracy of templates for navigated implantation made by rapid prototyping with DICOM datasets of cone beam computer tomography (CBCT)*, *Clin. Oral. Investig.*, 2011 Dec., 15(6), 1001–1006.
- [7] KIM B.C., LEE C.E., PARK W., KIM M.K., ZHENG GUO P., YU H.S., YI C.K., LEE S.H., *Clinical experiences of digital model surgery and the rapid-prototyped wafer for maxillary-orthognathic surgery*, *Oral. Surg. Oral. Med. Oral. Pathol. Oral. Radiol. Endod.*, 2011 Mar., 111(3), 278–85.e1. Epub 2010 Aug 9.
- [8] CIOCCA L., MAZZONI S., FANTINI M., PERSIANI F., BALDISSARA P., MARCHETTI C., SCOTTI R., *A CAD/CAM-prototyped anatomical condylar prosthesis connected to a custom-made bone plate to support a fibula free flap*, *Med. Biol. Eng. Comput.*, 2012 Mar., 24.
- [9] CIOCCA L., MAZZONI S., FANTINI M., MARCHETTI C., SCOTTI R., *The design and rapid prototyping of surgical guides and bone plates to support iliac free flaps for mandible reconstruction*, *Plast. Rec. Surg.*, 2012 May, 129(5), 859e-61e.
- [10] CIOCCA L., FANTINI M., MAZZONI S., PERSIANI F., MARCHETTI C., SCOTTI R., *CAD/CAM guided secondary mandibular reconstruction of a discontinuity defect after ablative cancer surgery*, *J. Craniomaxillofac Surg.*, 2012 Apr., 30.
- [11] HIDALGO D.A., *Fibula free flap: a new method of mandible reconstruction*, *Plast. Reconstr. Surg.*, 1989, 84, 71–79.
- [12] CORDEIRO P.G., DISA J.J., HIDALGO D.A., QUN Y.H., *Reconstruction of the mandible with osseous free flaps: a 10 year experience with 150 consecutive patients*, *Plast. Reconstr. Surg.*, 1999, 104, 1314–1321.
- [13] FERRARI S., RAFFAINI M., BIANCHI B., SESENNA E., *Secondary oro-mandibular reconstruction using revascularized bone flaps*, *Minerva Stomatol.*, 1998, 47, 75–85.
- [14] ISELI T.A., YELVERTON J.C., ISELI C.E., CARROLL W.R., MAGNUSON J.S., ROSENTHAL E.L., *Functional outcomes following secondary free flap reconstruction of the head and neck*, *Laryngoscope*, 2009, 119, 856–860.