

*pantomographic radiograms, miniplate osteosynthesis
relative faction dislocation coefficient*

Aleksander LAMŻA^{*}, Zygmunt WRÓBEL^{*},
Magdalena JEĐRUSIK-PAWŁOWSKA^{**}, Jan DRUGACZ^{**}

COMPUTER ASSESSMENT OF CORRECTNESS OF MANDIBLAR BONES FRACTURE SLIT INTEGRATION BASED ON PANTOMOGRAPHIC RADIOGRAMS

The method of objective assessment of the correctness mandible bones fracture slit was proposed in the research. At present, treatment results are evaluated by comparing pantomographic pictures made before and after integration. It is not an objective method; the estimation of the integration correctness coefficient is not possible, either. The use of computer processing enables introducing the relative mandible faction dislocation coefficient. Thanks to this, measurable determination of bone faction reposition correctness on pantomograms made after osteosynthesis is possible.

1. INTRODUCTION

Mandible, because of its anatomical position is the part of the maxillofacial skeleton most exposed to traumas. Thus, mandible fractures are the most common fractures of skull bones [3].

In the case of mandible fracture suspect, the X-ray picture in two projections at least as well as pantomographic picture are made. Pantomographic (panoramic) radiogram is made using orthopantomographic camera. Tomographic system of orthopantomograph consists of the X-ray tube with a collimator which narrows to ca 12 mm the rays beam incidenting on the photographic film, and photographic film in a cassette placed in a moving device which hold and carry the cassette. The X-ray tube – photographic plate system rotate around the common axis. Rotary motion is synchronized with straight-line motion of the photographic film so as to expose successive fragments of the film in successive phases of rotary motion. Jaw and mandible shape is not a circular sector; it is rather the ellipse, so it is necessary to apply two or more axis of rotation of tomographic system so that the required layer (mandible and upper jaw) will be visible in the picture [1]. Thus, the pantomogram of the facial area of the skull is a radiological picture in which teeth of both jaws and the adjacent areas are shown. Pantomographic pictures are used not only in diagnosis but also in assessment of mandible fracture treatment results [4, 6, 8].

* Computer Science Department, University of Silesia, 41 – 200 Sosnowiec ul. Będzińska 39

** Department of Oral and Maxillofacial Surgery Silesian Medical Academy in Katowice; 40-952 Katowice, Francuska 20/24

Treatment results assessment consist in comparing the pantomogram made after mandible factions integration with the pantomogram preceding the operation. This assessment is subjective and depends on the doctor's experience.

2. PURPOSE OF RESEARCH

The purpose of research was to make it possible to elaborate a method that makes objective assessment of mandible faction reposition based on pantomographic pictures.

3. MATERIAL AND METHODS

The research material comprised pantomographic pictures of patients surgically cured using miniplate osteosynthesis in Department of Oral and Maxillofacial Surgery Silesian Medical Academy in Katowice in the years 1998 – 2001. 35 pairs of pantomograms with 49 pairs of fracture slits were qualified to this research.

Because they were made using a conventional orthopantomograph it was necessary to scan them. The scanner used in the research enabled transparent scanning. The resolution of scans was 300 dpi, so the pictures were adequately large – ca. 3000×1600 pixels. Diminishing the resolution would make the picture less precise thus the precision of determining the points necessary for the analysis would be lower. The pictures were saved uncompressed in the bmp format, and the size of a single file was about 4.5 MB.

After loading a pair of pictures, they are subjected to initial processing [2]. Since the X-ray pictures are characterized by variable density, they have to be brightened or darkened. It is achieved by correction of the histogram as based on average density of the picture [5, 7, 9]. Thanks to this, brightness of the pictures is comparable.

As it was mentioned before, the surgery correctness assessment is made basing on comparison of two pantomograms – before and after the integration. In spite of using standardized positioning of patient's head in ortopantomograph it was impossible to omit the differences and distortions in both pictures. Another problems the different and heterogeneous scale of transformation - sometimes the pictures are stretch e.g. only vertically. Such distortions are caused by dislocation bone faction, e.g. "forward" or "backward" beyond the camera focus layer and inadvertent movement of patient's head during the photographing. Because of the above-mentioned problems, comparison of the unprocessed pictures is not possible.

Thanks to setting reference points in both pictures mutual scaling of the measured distances is possible and thus enabling the comparison of them. The position of the mandible factions will surely be different in both pictures because the factions dislocate in relations to each other. In that case, the reference points should be set on the upper jaw. Placing the first point on the left side of picture, the second on the right side and the third in the middle form the optimal lay-out (Fig. 1).

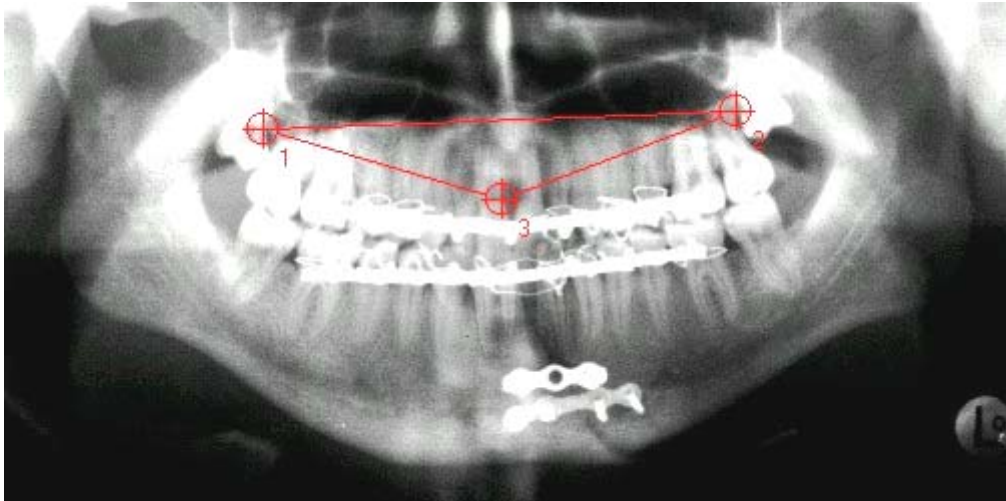


Fig.1. The optimal lay-out of reference points

The three reference points create a triangle in which the mutual ratios of the length of triangle sides projection on X-axis and Y-axis are measured (Fig. 2).

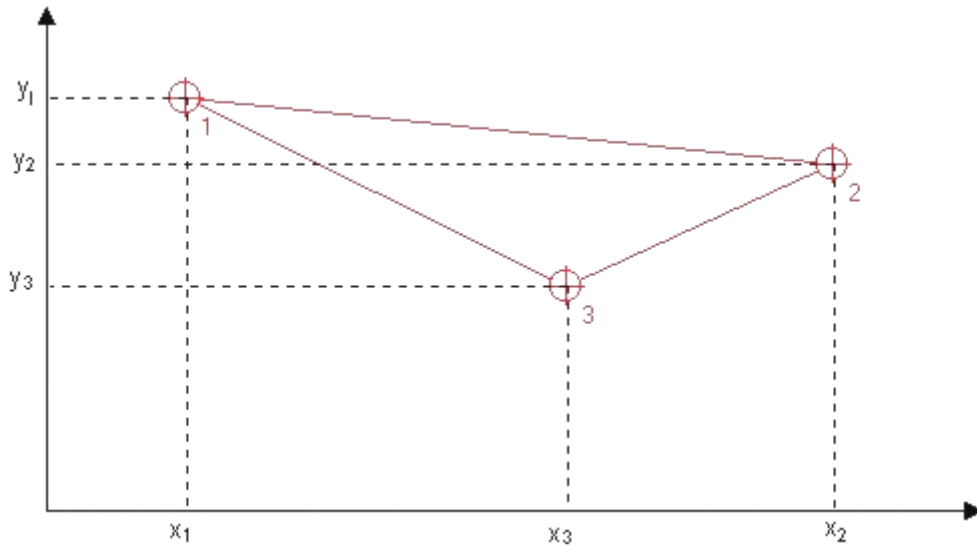


Fig.2. Graphical interpretation of the correction coefficient determining method

$$kx = \frac{|x_2 - x_1|}{|x_3 - x_1|} \quad (1a)$$

$$ky = \frac{|y_2 - y_1|}{|y_3 - y_1|} \quad (1b)$$

In that way two correction coefficients are determined (kx – horizontal coefficient, ky – vertical coefficient) used in calculations of all other distances.

The mutual bone fraction position is determined on the basis of distance between the fraction's edges. Points should be set on the edges of the bone fraction, which are physiologically (without a fracture) adjacent. These points are set in the picture before and after osteosynthesis (Fig. 3a and 3b). The choice of the points depends on the doctor – user of the program.

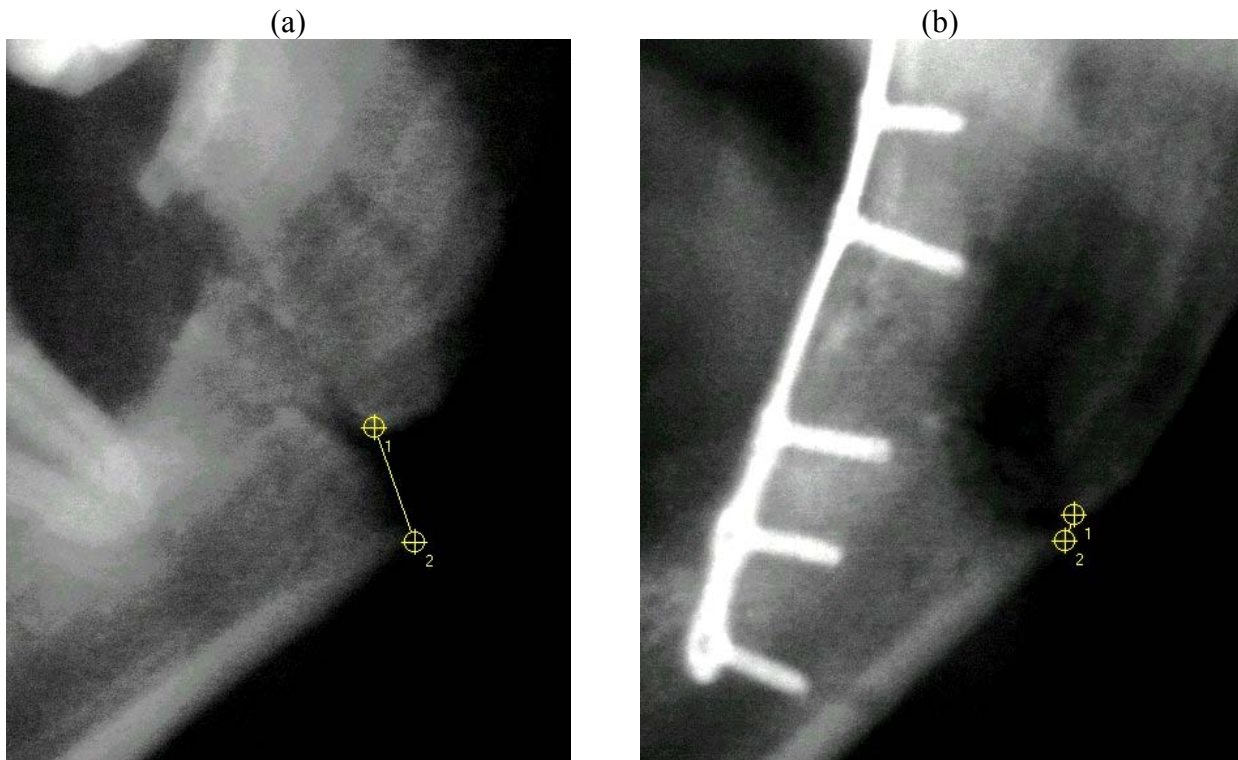


Fig.3. Measurement points before (a) and after osteosynthesis (b).

After setting the points, the distance between them is calculated. This length is not given in standard units (e.g. mm) as every picture would have to be additionally calibrated. It would be very problematic and practically impossible without modifying the way of making the pictures. The calculation of the distances is made using the correction coefficients kx , ky (equation 1a and 1b):

$$l_i = \sqrt{[kx \cdot (x_2 - x_1)]^2 + [ky \cdot (y_2 - y_1)]^2} \quad (2)$$

where:

- $i = 1$ (dislocation “before”) or 2 (dislocation “after”),
- (x_1, y_1) and (x_2, y_2) are distance measurement points coordinates.

These distances are determined for both pictures – before and after. To compare the osteosynthesis results objectively, relative coefficient describing mutual dislocation of bone fracture had to be brought. It is a function of distance between the fractions in picture before (l_1) and after osteosynthesis (l_2):

$$dl = \frac{l_1 - l_2}{l_1 + l_2} \tag{3}$$

The graphical interpretation of the formula (3) is shown in the graph below (Fig. 4):

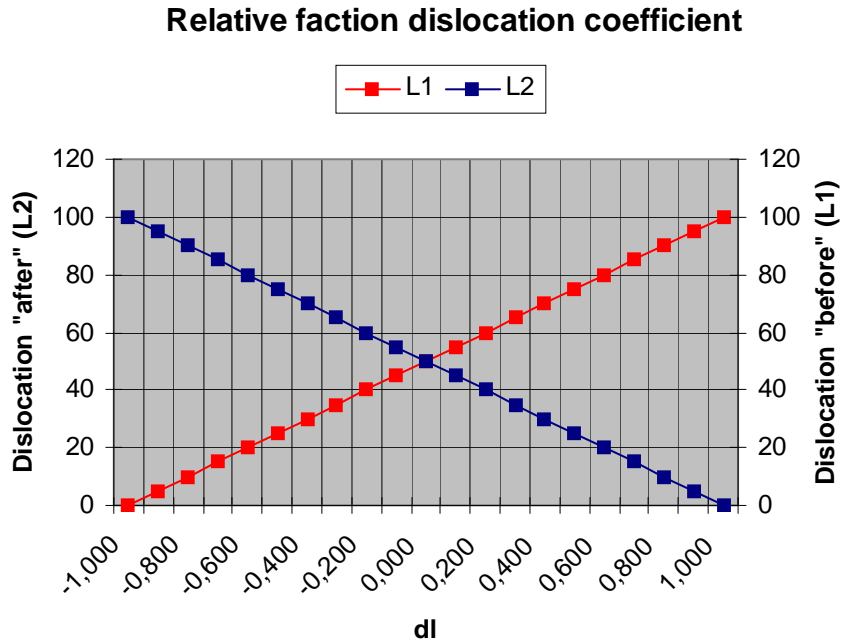


Fig.4. Relative faction dislocation coefficient

Values of the *dl* coefficient range from -1.000 to 1.000 . The interpretation of the coefficient value is presented in the table below (Tab. 1).

<i>dl</i> coefficient value	Interpretation
$\langle -1,000; 0 \rangle$	incorrect integration – the distance between faction after the reposition is longer than before surgery
0	no changes in distance between factions
$\langle 0; 1,000 \rangle$	correct integration – the distance between faction after the reposition is shorter than before surgery

Tab.1. The interpretation of the *dl* coefficient value

4. RESULTS AND CONCLUSIONS

Introducing the relative faction dislocation coefficient made it possible to compare and determine correctness of the mandible factions integration. Treatment results analysis using set of pictures is possible thanks to normalizing coefficient range.

Now, the first program version is being tested. It is open for changes and innovations. In the testing period, a few possibilities of the program expanding were noticed:

1. Adding to the program complete acquire unit supporting scan process (automatic resolution, brightness and contrast fitting, etc.).
2. Elaborating and implementing the method of wasteless picture compression to minimalize pantomograms database.
3. Minimalizing the effects of picture distortion caused by 3D to 2D space transformation during taking the picture on the measurement results.

The program will be tested, developed and rationalized all the time according to the needs. Nevertheless, the method of assessment as well as the notion of relative faction dislocation coefficient seems to be valid.

BIBLIOGRAPHY

- [1] Red. PRUSZYŃSKI B., Diagnostyka obrazowa – podstawy teoretyczne i metodyka badań, PZWL, Warszawa 2000.
- [2] KASIŃSKI A., PIAŚCIK T., Poprawianie czytelności rentgenogramów czaszki i interaktywne wspomaganie pomiarów biometrycznych, TIM'99, BP65-72.
- [3] KRYST L. Chirurgia szczękowo-twarzowa. Wydawnictwo Lekarskie PZWL 1993.
- [4] KRYST L., PIEKARCZYK J., MLOSEK K., WANYURA H., SZMURZYŁO W., BARAMOW P., SIEMIŃSKA-PIEKARCZYK B. Ocena odległych wyników leczenia złamań żuchwy. Czas. Stomat., 1990, 63, 85-90.
- [5] KUCHARIEW G., Przetwarzanie i analiza obrazów cyfrowych, Wydawnictwo Uczelniane Politechniki Szczecińskiej, Szczecin 1998.
- [6] RIX L., STEVENSON A. R., PUNNIO-MORTHY A. Analysis of 80 cases of mandibular fractures treated with miniplate osteosynthesis. Int. J. Oral. Maxillofac. Surg., 1991, 20, 337-341.
- [7] SMITH S.W., The Scientist and Engineer's Guide to Digital Signal Processing, California Technical Publishing, San Diego 1999.
- [8] TOMASZEWSKI T., STODÓLKIEWICZ A., KOLIŃSKI P., BARTOSZCZE-TOMASZEWSKA M. Zastosowanie mini i mikroplątek w leczeniu złamań kości czaszki twarzowej. Mag. Stomat., 1997, 1, 18-21.
- [9] WATKINS C.D., SADUN A., MARENKA S., Nowoczesne metody przetwarzania obrazu, WNT, Warszawa 1995.