

## HEART SEGMENTATION IN ECHO IMAGES

**Andrzej Skalski, Paweł Turcza**

AGH University of Science and Technology, Faculty of Electrical Engineering, Automatics, Computer Science and Electronics, Department of Measurement and Instrumentation, al. Mickiewicza 30, 30-059 Cracow, Poland. (✉ skalski@agh.edu.pl, turcza@agh.edu.pl, +48 12 617 2828)

### Abstract

Cardiovascular system diseases are the major causes of mortality in the world. The most important and widely used tool for assessing the heart state is echocardiography (also abbreviated as ECHO). ECHO images are used e.g. for location of any damage of heart tissues, in calculation of cardiac tissue displacement at any arbitrary point and to derive useful heart parameters like size and shape, cardiac output, ejection fraction, pumping capacity. In this paper, a robust algorithm for heart shape estimation (segmentation) in ECHO images is proposed. It is based on the recently introduced variant of the level set method called level set without edges. This variant takes advantage of the intensity value of area information instead of module of gradient which is typically used. Such approach guarantees stability and correctness of algorithm working on the border between object and background with small absolute value of image gradient. To reassure meaningful results, the image segmentation is proceeded with automatic Region of Interest (ROI) calculation. The main idea of ROI calculations is to receive a triangle-like part of the acquired ECHO image, using linear Hough transform, thresholding and simple mathematics. Additionally, in order to improve the images quality, an anisotropic diffusion filter, before ROI calculation, was used. The proposed method has been tested on real echocardiographic image sequences. Derived results confirm the effectiveness of the presented method.

Keywords: echocardiography, image segmentation, level set method, Hough transform, shape estimation.

© 2011 Polish Academy of Sciences. All rights reserved

### 1. Introduction

Every year cardiovascular system diseases are the reason of over 7 million premature demises in the world. One of the main cardiovascular risk factors is hypertension, leading among others to left ventricle (LV) rebuilding. In Poland, cardiovascular system diseases are responsible for about half of all demises. The people under 65 represent almost of 20% of this number. According to the Polish Acute Coronary Syndromes (PL-ACS) register 152 452 hospitalizations had been noted because of ACS from October 2003 to February 2007 [1].

Estimation of left ventricular shape in ultrasonic echocardiographic images (ECHO) is recognized as the one of the main non-invasive methods of assessing the risk of heart and cardiovascular diseases. Due to the complexity of heart internal structures, the presence of strong disturbances in ultrasonic images (speckles, specular reflections, echoes, shadows, Gaussian noise of electronics) and low contrast in case of fine structures, LV shape estimation is a difficult and time-consuming task. Evaluation of LV rebuilding progression in time is an additional challenge due to very high value of estimation error as a result of significant distinctions in LV outline produced by different physicians.

In this context, development of an automatic and robust LV shape estimation method performed in real-time is very important [2]. Taking into account features of the USG data source, such method should consist of:

- initial filtration aiming at reduction of disturbances and edge enhancement,
- initial image segmentation aiming at approximate calculation of region of interest,

- iterative estimation of LV shape by image segmentation procedure.

From the technical point of view, heart structures outline performed by a medical doctor during LV shape estimation is equivalent to image segmentation. The image segmentation process can be understood as image data division to the separable subsets. In case of medical images, received results should correspond to real anatomical structures. In other words, as a result of the segmentation procedure applied to ECHO data one should receive a wall of heart or chamber shape estimation. Examples of interesting ECHO structures are presented in Fig. 1.

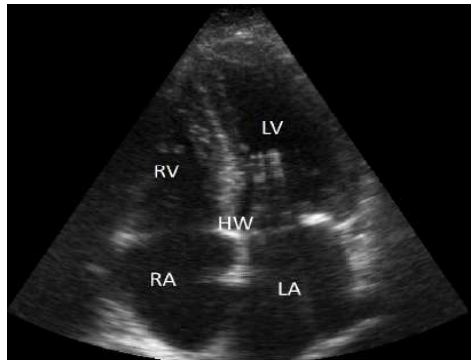


Fig. 1. - Example of ECHO image, four chamber view, RV – right ventricle, LV - left ventricle, RA - right atrium, LA - left atrium, HW – Heart walls (image obtained from: Department of General Medicine and Geriatrics, Collegium Medicum, Jagiellonian University, Krakow)

Image segmentation algorithms usually use the information contained in the image as the basis for its action. The simplest image segmentation methods are based on thresholding [3] operation. Such methods use the pixel value directly to classify the given pixel as an object or a background i.e.: if the pixel value fulfils the given condition, the pixel is classified as the background, in the opposite case as the object. The threshold value, for the classification process can be specified manually by the user or it can be computed by the algorithm based on e.g. the image histogram. More advanced algorithms use the information about the neighbourhood of each pixel (e.g., *region growing algorithm*).

Another group of algorithms are model based methods. An *active contour* (or a *snake*) proposed by Kass [2] is the most recognized example of such an approach. It uses a curve evolving in time as a model of the boundary of the segmented object in the image. The level set algorithm [4, 5] is another, yet more versatile method. The level set approach uses the zero level of the evolving surface (3D) to represent the boundary in the 2D segmented image.

The problem of effective segmentation and heart structure tracking in echocardiographic images is the current research topic widely considered in the literature [6-11].

In the paper, a novel approach to echocardiographic segmentation based on Level Set method using information about value arrangement is presented. Section 2 consists of the idea and description of the Region of Interest calculation and segmentation technique. Evaluation and estimation results, visual examination and quantitative analysis are shown in section 3. The last section consists of a conclusion and description of future works.

## 2. Echocardiographics image segmentation

### 2.1 Proposed method – the idea

The proposed method of heart segmentation in echocardiographic images is based on three main steps. The first step is responsible for ultrasonic image de-noising. The dominant noise

in ultrasonic images is the multiplicative noise known as speckle. Since most of the information in ultrasonic images is edges based, an appropriate denoising filter should concurrently remove noise and protect or even enhance existing edges in the image. For this purpose a nonlinear diffusion filter has been applied [12] in the proposed algorithm. In the second step an area of image undergoing segmentation is restricted to the diagnostically relevant part. For this purpose an automatic algorithm based on Hough transformation [13] is proposed (Fig. 2). The last step of the algorithm is the image segmentation. For this purpose the active contour algorithm implemented by the level set method [4, 5] in Chan-Vese [14] variant is used.

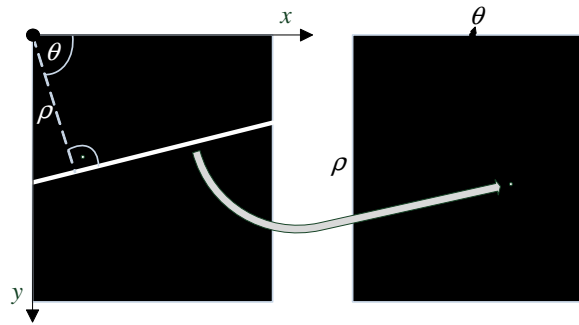


Fig 2. Line detection based on Hough transform and Hough space for a single line

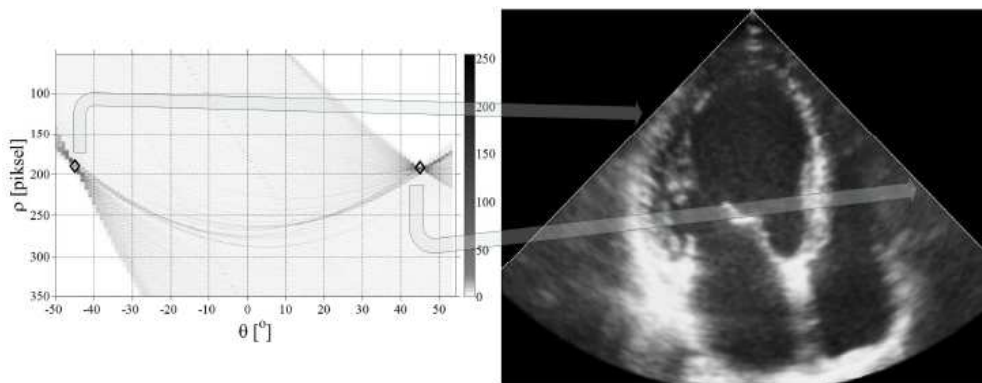


Fig. 3. Example of Hough space and lines computed from equation 1 based on the maximum value of Hough transform

## 2.2 An automatic determination of image area for segmentation

A heart ultrasonic image is produced by object sectoral scanning with many ultrasonic beams. The diagnostically relevant part, also called *region of interest* (ROI) is a cone-shaped structure in the ultrasonic image. The rest part of the rectangular image (see Fig. 3) is assigned a zero value by the device. The value of a pixel inside the ROI depends on the reflection level of the object that is represented by the pixel. The most reflective parts are the tissue boundaries, in contrast to homogeneous tissue or blood that almost do not reflect the ultrasonic beam. Therefore, the heart chambers are almost black, whereas their walls are relatively white. This property causes the segmentation algorithm possible to make an error, i.e. to treat the background as an object. In order to avoid such situation, the authors propose an automatic method to restrict the segmentation area to the diagnostically essential part only.

In the first step the algorithm computes a binary mask - an approximation of the ROI. In this operation image thresholding with the threshold set on 30 is used. Subsequently, the

Hough transform [14] of the obtained binary mask is computed. The values of the Hough transform represent the length of the lines with the coordinates  $(\theta, \rho)$  in the image (see Fig. 2). The cone-shaped ROI (see Fig. 3) is limited by two straight lines and an arc. In the image space the straight line  $l(x, y)$  is represented by the equation

$$y = -ctg(\theta) \cdot x + \frac{\rho}{\sin(\theta)}, \quad (1)$$

where  $\rho$  – is the distance between the line  $l$  and the origin, whereas  $\theta$  is an angle of the vector from the origin to the closest point on the line ( $\rho$  is the length of this vector) (see Fig. 2).

Parameters  $(\theta, \rho)$  of two lines limiting the ROI are determined by examination of the values of Hough transform coefficients. The coordinates of two coefficients that have the highest values and  $\theta$  with opposite sign are picked up as the sought parameters  $(\theta, \rho)$ .

The coordinates of the centre of the arc (limiting the ROI from the bottom) are equal to the coordinates of the intersection of two limiting lines. The radius of the arc is equal to the distance from the arc centre to the opposite border point of the binary mask.

### 2.3 ECHO images segmentation

Boundaries of heart structures that are visible in ECHO images usually get blurred and corrupted by noise. Therefore the method for segmentation of echocardiographic images proposed in the paper is based on an active contour model that is implemented by the level set method in Chan-Vese variant [14].

The AC algorithm models the segmented object boundary with a parametric curve  $C(s) = (x(s), y(s))$ , which is evolving in time. The parameter  $s \in [0,1]$  is a normalized arclength of the curve  $C(s)$  and  $x(s)$  and  $y(s)$  are points on it. The curve evolution process is controlled by two influencing forces. The internal force associated with the contour internal energy  $E_{int}$  is responsible for keeping the contour smooth, continuous and short. The external force associated with contour external energy  $E_{ext}$  is responsible for attracting the curve towards the object boundary. The *external energy* is supposed to be minimal when the contour reaches the object boundary position. Evolution of the classical AC is related to the energy minimization problem that can be stated as [2]:

$$E = \int_0^1 E(C(s)) ds = \int_0^1 E_{int}(C(s)) ds + \int_0^1 E_{ext}(C(s)) ds, \quad (2)$$

where:

$$E_{int} = \frac{\alpha(s)|C_s(s)|^2 + \beta(s)|C_{ss}(s)|^2}{2}, \quad (3)$$

$C_s(s)$  and  $C_{ss}(s)$  denote the first and the second derivative of  $C(s)$  in respect to  $s$ , respectively,  $\alpha, \beta$  are coefficients weighing the curve internal energy.  $E_{ext}$  has a form of an edge detector in most of practical applications e.g.:

$$E_{ext} = -\|\nabla I(x, y)\|^2, \quad (4)$$

where  $I(x, y)$  denotes the intensity of an image point with coordinates  $(x, y)$  and  $\nabla = [\partial/\partial x, \partial/\partial y]^T$  is a gradient operator.

A very popular gradient-based edge estimator (4) is sensitive to image noise. Moreover, its application possibly leads to large segmentation errors, when object boundaries are not well defined (not sharp enough). In such cases methods based on the image area intensity value

like the one proposed by Chan and Vese [14] are more appropriate. The algorithm proposed by Chan-Vese tries to divide the image  $I$  into two disjointed parts that are represented by two constants  $c_1$  and  $c_2$ . The segmentation problem as described by Chan-Vese can be stated as an energy minimization problem:

$$F(C, c_1, c_2) = \mu \cdot len(C) + \gamma \cdot area(inside C) + \lambda_1 \int_{inside(C)} |I(x, y) - c_1|^2 dx dy + \lambda_2 \int_{outside(C)} |I(x, y) - c_2|^2 dx dy \quad (5)$$

Additional regularization terms in (5) are the length of the curve ( $len(C)$ ) and the area of the region inside the curve  $C$  ( $area(inside C)$ ). The use of the image intensity value inside and outside curve  $C$  as an information-controlling curve evolution instead of the most commonly used gradient information (4) is the main advantage of approach (5).

In the proposed algorithm the curve  $C$  in equation (5) is represented by the zero level of function  $\phi$  which is called the level set function [6]:

$$C = \{(x, y) | \phi(x, y) = 0\}. \quad (6)$$

The signed distance function is used as the level set function  $\phi$ . In such formulation the image area inside the curve  $C$  is represented by a set of points  $(x, y)$  for which  $\phi(x,y) > 0$  e.g.  $inside(C) = \{(x, y) | \phi(x, y) > 0\}$  and similarly, the image area outside the curve  $C$  as  $outside(C) = \{(x, y) | \phi(x, y) < 0\}$ .

Using the level set function  $\phi$ , equation (5) can be written as:

$$F(\phi, c_1, c_2) = \mu \cdot len(\phi = 0) + \gamma \cdot area(\phi \geq 0) + \lambda_1 \int_{\phi > 0} |I(x, y) - c_1|^2 dx dy + \lambda_2 \int_{\phi < 0} |I(x, y) - c_2|^2 dx dy \quad (7)$$

Minimization of the above functional leads to the Euler-Lagrange equation. It leads to evolution equation after introducing an artificial time [14]:

$$\frac{\partial \phi}{\partial t} = \delta_\varepsilon(\phi) \left[ \mu \cdot div \left( \frac{\nabla \phi}{|\nabla \phi|} \right) - \gamma - \lambda_1 (I - c_1)^2 + \lambda_2 (I - c_2)^2 \right] = 0, \quad (8)$$

where  $\mu \geq 0$ ,  $\gamma \geq 0$ ,  $\lambda_1 > 0$ ,  $\lambda_2 > 0$  are fixed parameters. The delta function after regularization has the form of:

$$\delta_\varepsilon(\phi) = \frac{1}{\pi} \cdot \frac{\varepsilon}{\varepsilon + \phi^2}, \quad (9)$$

and  $\varepsilon > 0$  is a small regularization term.

Representing an evolving curve as a zero level set of function  $\phi$  eliminates the problem occurring when the evolving curve changes its topology e.g. splits or merges. In level set formulation curve splitting or merging is equivalent to splitting or merging sets of image points  $(x,y)$  for which  $\phi(x,y)$  has a constant sign.

An initial contour has to be supplied in order to start the evolution process. The curve obtained from the current image segmentation can be used as a starting curve for the next image when segmenting image sequence representing a heart systole. In such cases, the initial contour has to be supplied for the first frame only. It can be either a contour drawn manually by the user or derived automatically by an algorithm.

In the discussed method the initial contour is represented by an ellipse. The centre of the ellipse is pointed out by the user near the centre of the segmented structure e.g. the left

ventricle. Other ellipse parameters are derived by morphological processing of a binary mask that is obtained by thresholding (threshold set to 30) an ECHO image. First, the small details are removed by the opening operation. Next, weak connections between objects are removed by eroding operation. In the result, a binary approximation of heart structures in the image is obtained. Chambers are represented by the compact sets of mask elements (pixels) with value 1, whereas walls by elements of 0 value. Finally, the set of mask elements for which the centre point provided by the user belongs is chosen. It is used as a basis for ellipse parameters calculation. Due to eroding operation, the determined ellipse fits inside the segmented object.

### 3. Method evaluation and estimation results

The described algorithm has been tested on a few real echocardiography images sequences obtained from the Department of General Medicine and Geriatrics, Collegium Medicum, Jagiellonian University, Cracow, Poland.

Assessment of the heart shape estimation quality should consist of two parts. The first one is the shape estimation in ECHO data, and second: the shape mapping accuracy of medical imaging devices (e.g. Computed Tomography [15]). The authors focussed on the first part and assessed segmentation quality in comparison with manual contouring by experts.

A set of 6 exemplary frames chosen from the ECHO obtained sequences is shown in Fig. 4. In this figure, white contours mark the shapes of the left ventricle estimated by the proposed method. It can be observed that the results are also correct when the boundary in the left part of the images is not present. The algorithm is working stably all the time and the contour evolution is kept inside a diagnostically relevant area.

When the shape of the left ventricle is estimated, one can easily calculate changes of the area of the left ventricle during heart systole. In Fig. 5, deviation of estimated area of the left ventricle in time from its mean value is presented. Corresponding frames from Fig. 4 are marked by arrows with numbers. The shape of the curve from Fig. 5 together with its periodicity (regularity) can be a valuable information of chamber behavior in time.

In all the experiments, parameters of the algorithm were set in the following way:  $\mu=2$ ,  $\gamma=1$ ,  $\lambda_1=1$ ,  $\lambda_2=1$ . The number of iterations was 70, whereas the size of one image frame was 396 by 531 pixels. The proposed algorithm was implemented in Matlab language on Intel Core 2 Quad 2.66 GHz, 2 GB RAM. Its computational complexity in terms of time spent for the calculation of one image frame is: 119.58 s which includes 0.4 s for image denoising, 0.18 s for ROI calculation and 1.7 s for one iteration of the contour evolution.

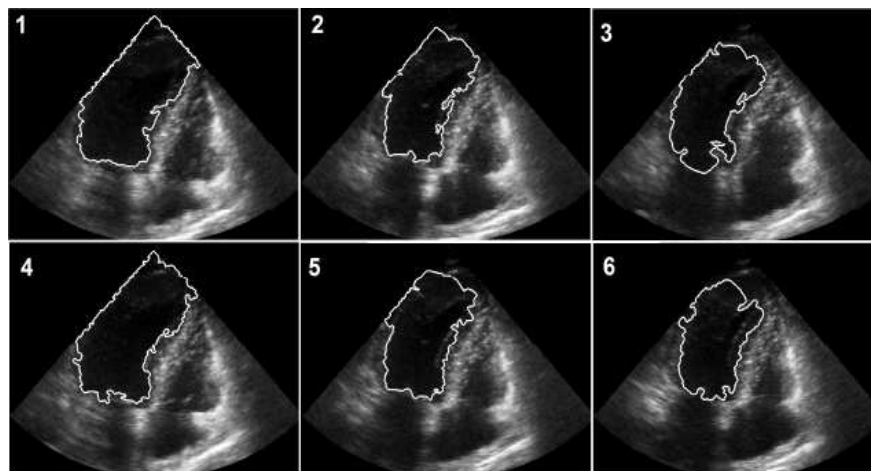


Fig. 4. Segmentation results using the proposed method. Picture numbers represent the place in ECHO sequence marked in Fig. 5

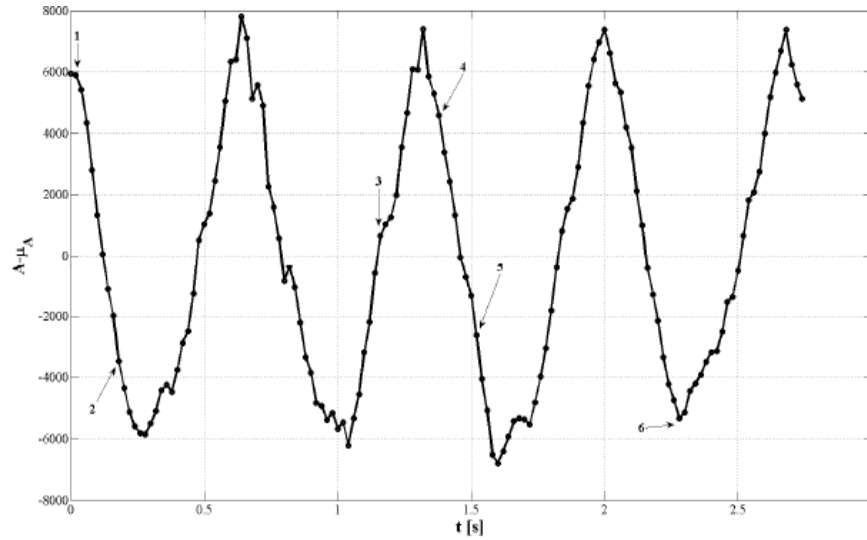


Fig. 5. Area minus mean value of received contours waveform. Arrows with numbers indicate places of pictures from Fig. 4 in the ECHO sequence

In order to evaluate the shape estimation accuracy, the results were compared with manual outlines done for 132 real ECHO by an expert, which is a gold standard in this case. Evaluation was carried out on the methodology presented in [16]. Three parameters for each frame were calculated: *True Positive Fraction (TPF)*, *False Negative Fraction (FNF)* and *False Fraction (FF)* defined as:

$$\mathbf{TPF} = \frac{\sum_{x=1}^N \sum_{y=1}^M \mathbf{M}_{\mathbf{TP}}(x, y)}{\sum_{x=1}^N \sum_{y=1}^M \mathbf{I}_{\mathbf{EST}}(x, y)} = \textit{sensitivity}; \quad (10)$$

$$\mathbf{M}_{\mathbf{TP}}(x, y) = \begin{cases} 1 & \text{for } \mathbf{I}_{\mathbf{GT}}(x, y) = \mathbf{I}_{\mathbf{EST}}(x, y) = 1; \\ 0 & \text{for other cases} \end{cases}; \quad (11)$$

$$\mathbf{TNF} = \frac{\sum_{x=1}^N \sum_{y=1}^M \mathbf{M}_{\mathbf{FN}}(x, y)}{\sum_{x=1}^N \sum_{y=1}^M \mathbf{I}_{\mathbf{EST}}(x, y)} = \textit{specificity}; \quad (12)$$

$$\mathbf{M}_{\mathbf{FN}}(x, y) = \begin{cases} 1 & \text{for } \mathbf{I}_{\mathbf{EST}}(x, y) = 0 \wedge \mathbf{I}_{\mathbf{GT}}(x, y) = 1; \\ 0 & \text{for other cases} \end{cases}; \quad (13)$$

$$\mathbf{FF} = 1 - \frac{\sum_{x=1}^N \sum_{y=1}^M |\mathbf{I}_{\mathbf{GT}}(x, y) - \mathbf{I}_{\mathbf{EST}}(x, y)|}{\sum_{x=1}^N \sum_{y=1}^M \mathbf{I}_{\mathbf{GT}}(x, y)}, \quad (14)$$

where  $\mathbf{I}_{\mathbf{GT}}(x, y)$  – binary mask which represents the results from the manual contouring,  $\mathbf{I}_{\mathbf{EST}}(x, y)$  – binary mask which represents the results from the proposed method (1 means object, 0 - background).

**TPF** gives us information on the number of pixels belonging to the object (in this case ventricle), which were classified correctly. On the other hand, **FNF** tells us the number of pixels in the frame which were not classified as an object by the automatic algorithm with reference to ground true. Finally, **FF** representing a wrong classification takes place when during manual contouring a pixel was classified as an object but in the automatic method it was not and the opposite way.

The obtained results for the proposed method in a histogram form are presented in Fig. 6. Additionally, average values of coefficients (10), (12), (14) calculated from results presented in Fig. 6, are shown in Table 1.

In order to evaluate the quality (e.g. variation and repeatability) of manual contouring, which is a reference to our method, two experts 10 times each (in different moments of the day), manually contoured the same, randomly chosen image frame. In Fig. 7 we can see all of the contours plotted by the experts with marked mean shape. Subsequently, **FPF**, **FNF** and **FF** factors were calculated using a mean shape of these 20 contours as a ground true (Table 1),  $I_{GT}(x,y)$  was a mean shape and  $I_{EST}(x,y)$  was a single contouring.

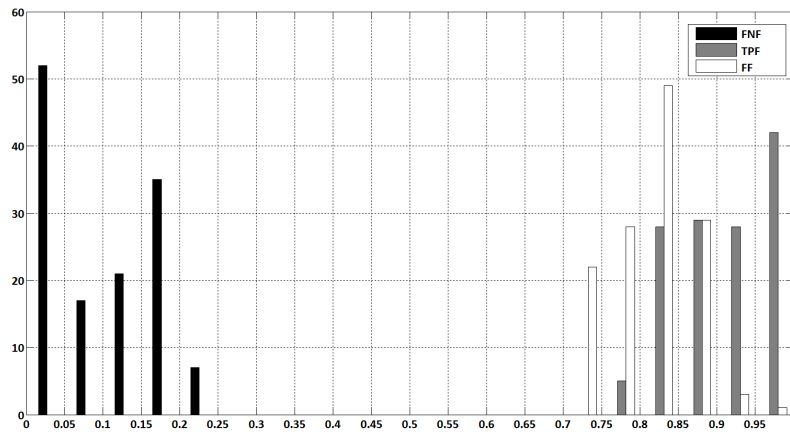


Fig. 6. Histogram of FNF, TPF, FF values for results of the proposed method

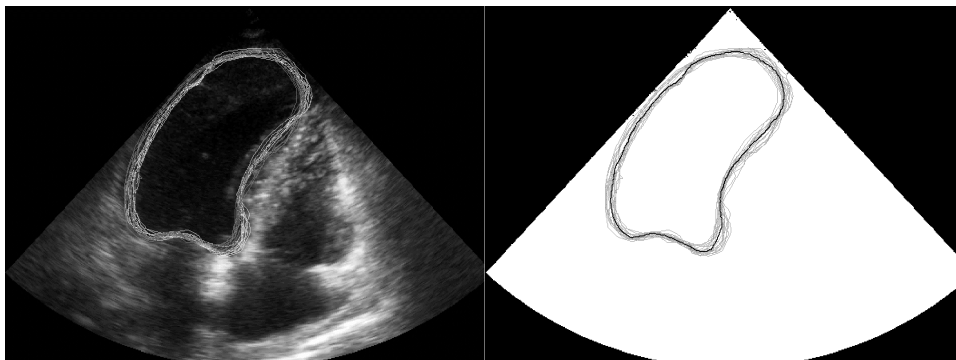


Fig. 7. Variation in manual contouring (left) and contours along plotted on white background with mean contour marked as black line (right)

From **TPF** turns out that on average 4 % of pixels belonging to the mean contour, which was our ground true, were not outlined by experts at all. A lower value of **FF** and **TPF** is caused by the different size of the segmented structure (factors have relative value, e.g. one wrongly classified pixel for a structure which consists of 100 pixels decrease **TPF** by 0.01, for a structure which consists of 1000 pixels it decreases only by 0.001) and problems with poor quality of the heart border in some frames. Therefore, it is practically impossible to asses



the image segmentation algorithm quality using numerical values of **FPF**, **FNF**, **FF** only. Numerical values of the mentioned factors should be always considered together with a visual inspection of the results as it is presented in Fig. 4 and 5. Visual examination confirms the effectiveness of the proposed method.

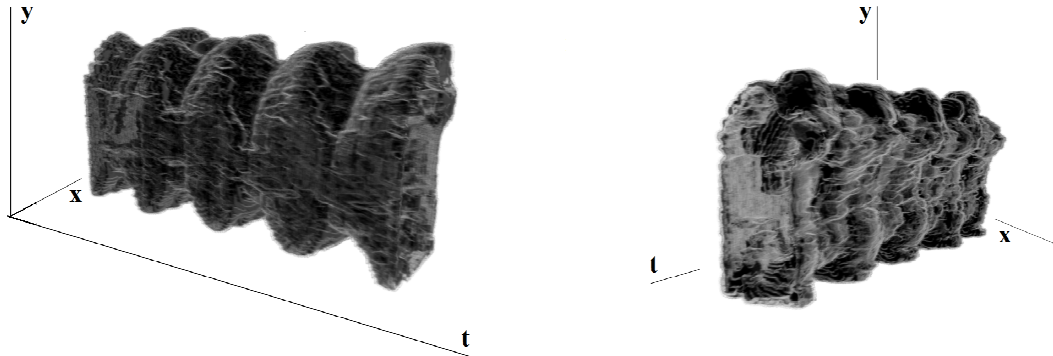


Fig. 8. 3D visualization of exemplary results

Table 1. Average value of **TPF**, **FNF**, **FF**

	<b>TPF</b>	<b>FNF</b>	<b>FF</b>
<b>Proposed Method</b>	0.91	0.10	0.82
<b>Variation of Manual Contouring for one frame</b>	0.96	0.03	0.93

In Fig. 8 exemplary results for one whole sequence are presented after 3D reconstruction which allows to consider the shapes of the received contours within the whole set of data.

#### 4. Conclusions

A method for automatic segmentation of heart structures in ECHO images was proposed in the paper. The described algorithm involves the following three steps: removing multiplicative noise from an image by nonlinear diffusion filtration, determination of diagnostically relevant area by Hough image transformation, and finally image segmentation with active contour algorithm. Erroneous situations with pixels representing background are classified as an object by an algorithm were excluded by the proper restriction of the segmented area and controlling contour evolution process using information other than image gradient magnitude.

The efficiency of the proposed algorithm has been confirmed by the comparison of 132 real ECHO outlines from the proposed method with the ones provided by an expert. Gold standard requirements have been fulfilled.

In future work, the authors want to compare described algorithm with other techniques and use the proposed solution to calculate, important from a medical point of view, coefficients which describe the heart state.

#### Acknowledgements

Authors would like to express their appreciation to the workers of the Department of General Medicine and Geriatrics, Collegium Medicum, Jagiellonian University, Krakow,

Poland, specially to Prof. Tomasz Grodzicki, for making available ECHO images which were used in the research described in this paper. The work was supported by a Polish-Italian grant, decision no 363/N-Wlochy/2008/0.

## References

- [1] <http://www.rejestrozw.republika.pl/>
- [2] Kass, M., Witkin, A., Terzopoulos, D., (1988). Snakes: Active contour models. *International Journal on Computer Vision*, 1, 321-331.
- [3] Gonzalez, R.C., Woods, R.E. (2007). Digital Image Processing. *Prentice Hall*.
- [4] Osher, S., Sethian, J.A. (1988). Fronts propagating with curvature dependent speed: algorithms based on Hamilton-Jacobi formulations. *Journal of Computational Physics*, 114, 12 - 49.
- [5] Osher, S., Paragios, N. (2003). Geometric Level Set Methods in Imaging, Vision, and Graphics. *Springer-Verlag*. New York.
- [6] Ledesma-Carbayo, M.J. et al. (2005). Spatio-Temporal Nonrigid Registration for Ultrasound Cardiac Motion Estimation. *IEEE Transactions on Medical Imaging*. 24(9), 1113-1126.
- [7] Nascimento, J.C., Sanches, J.S., Marques, J.S. (2006). A Method the Dynamic Analysis of the Heart Using a Lyapunov Based Denoising Algorithm. *Proc. IEEE EMBC*, 4828-4831.
- [8] Bharali, U., Ghosh, D. (2006). Cardiac Motion Estimation from Echocardiographic Image Sequence using Unsupervised Active Contour Tracker. *Proc. ICARCV*.
- [9] Zhuang, L., et al. (2007). Volumetric Meshfree Framework for Joint Segmentation and Motion Tracking of the Left Ventricle. *Proc. ISBI*, 396-399.
- [10] Yang, L., et al. (2008). A Fast and Accurate Tracking Algorithm of Left Ventricles in 3D Echocardiography. *Proc. ISBI*, 221-224.
- [11] Luo, J., Konofagou, E.E. (2008). High-Frame Rate. Full-View Myocardial Elastography with Automated Contour Tracking in Murine Left Ventricles in Vivo. *IEEE Transactions on Ultrasonics, Ferroelectrics, and Frequency Control*, 55, 240-248.
- [12] Turcza, P. (10-14 May 2009). USG image denoising as an early stage In methods detecting common carotid artery intima-media thickness. *IX Symposium on Modelling and Measurements in Medicine: Krynica*, 171-174. (in Polish).
- [13] Duda, R.O., Hart, P.E. (1972). Use of the Hough Transformation to Detect Lines and Curves in Pictures. *Comm. ACM*, 15, 11-15.
- [14] Chan, T.F., Vese, L.A. (2001). Active contours without edges, *IEEE Transactions on Image Processing*, 10(2), 266-277.
- [15] Ryniewicz, A. (2010). Accuracy assessment of shape mapping using Computer Tomography. *Metrology and Measurement Systems*, XVII(3), 481-492.
- [16] Fenster, A., Chiu, B. (2005). Evaluation of segmentation algorithms for medical imaging. *Proceedings of the 2005 IEEE Engineering in Medicine and Biology 27th Annual Conference*, 7196-7189.