

## References

- [1] Cretu G., Berea I. Acupuncture in the treatment of trigeminal neuralgia and facial nerve paralysis //Rev. Chir. Oncol. Radiol. ORL Oftalmol. Stomatol. Otorinolaringol.- 1983.- Vol.28, №4.- P. 309 - 312.
- [2] Gavaa Luvsa. Essays for eastern acupuncture methods /Under red.V.N.Zibuljaka. – Novossibirsk: Nauka, 1991. - 432 p.
- [3] Matcheret E.L., Samossuk I.Z.. Manuscript for acupuncture. Kiev: "Vischa chkola", 1986. - 302 p.
- [4] Pohodenko-Chudakova I.O., Avdeeva E.A. Determination of acupuncture method application while complex treatment of traumatic neuritis of trigemini //Bel. Med. Journ. 2002.– N1.– P. 71 – 72.
- [5] Sermanov K.S., Mazurok F.S. Complex treatment of neuralgia of nervous trigemini (Laser acupuncture, phinlepsin) //Thes. rep. intern. symp. on laser surgery and medicine.- Samarkand, 1988.- V.2.- P. 317 - 319.
- [6] Weinberg S., Kryshtalskyj B. Analysis of facial and trigeminal nerve function after arthroscopic surgery of the temporomandibular joint //J. Oral Maxillofac. Surg.- 1996.- Vol.54, №1.- P. 40 - 43.

## OSTEOINTEGRATION UNDER INFLUENCE OF MAGNETOACUPUNCTURE (EXPERIMENTAL CASE)

I.O. POHODENKO-CHUDAKOVA, A.P. PILIPENKO

BELORUSSIAN COLLABORATING CENTER OF EACMFS,  
BELORUSSIAN STATE MEDICAL UNIVERSITY, MINSK, BELARUS

PUSHKIN AV. 33-239; PO BOX 190; 220092 MINSK, BELARUS  
E-MAIL: JP-C@TUT.BY

[ENGINEERING OF BIOMATERIALS, 58-60,(2006),20-21]

### Introduction

Human body tissue regeneration is one of actual medico-biological problems. According to the special medical literature, great attention is paid to the study of reparative regeneration of bone tissue for patients with surgical pathology of mandible [1]. At the same time the main problem is to find methods for tissue regeneration stimulation which have to correspond to two general requirements: 1) influence to reparative regeneration process must provide only realization of those capacities which have primary tissue under examination but not change regeneration possibilities; 2) performed influence must be harmless at maximum and do not provoke by-effects, aggravating factors are not to be caused.

This problem is also worthy of notice because of cranio-maxillofacial area injuries augmentation last years. So, quantity of traumatic fractures of mandible is increased and composes 67% - 85% [2,6]. At the same time, scientists of the world examine influence of different physical factors as well as magnetoacupuncture and alternative methods on the morphological characteristics of the bone tissue for the patients with diseases of osteoarticular system [4,5,7]. There important advantage before medicines is stimulation of microcirculation and immunological reactions and involve metabolism normalization. Till now, no information in official literature resources about magnetoacupuncture application with alternating magnetic field for stimulation of reparative processes of bone tissue of mandible after

traumatic injury.

**Aim** of the work is to study magnetoacupuncture influence on the regeneration of traumatic injuries of bone tissue of mandible in experiment.

### Materials and methods

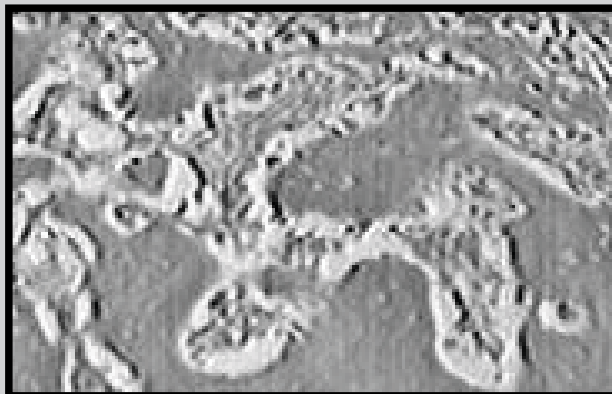
Research has been performed on the 12 dogs divided into two equal groups. Intravenous anesthetic of thiopental sodium 10% has been applied for all animals – 40 – 45 mg per 1 kg of animal weight. This method of anaesthesia gave possibility to do operation on the mandibular bone during 1,5 – 2 hours without additional medicines. 15 ml of thiopental sodium 10% has been applied for animals during the operation. This anaesthesia medicine was effective to avoid complications during anaesthesia course and at the end of operation when this course was finishing.

Operations have been performed in aseptic conditions. Incisions performed parallel to the edge of body of mandible in 1 sm from it. Sken, subcutaneous fat and platysma have been cut keenly. After periosteotomy and skeletonization of the horizontal segments of body of mandible, osteotomical cut has been performed at an angle of 80°-90° by dental drilling machine in the region of bottom edge. Neurovascular fascicle has been kept undamaged. We have extracted teeth, roots of which have been on the line of cut. Operation wound was treated with lincomycine hydrochloride 30% - 5 ml and sew up. Sutures have been treated with iodine. The same operations have been performed on the opposite side of the animal mandible. Postoperatively all animals have had 7 days antibacterial and antiphlogistic course. Animals of the I-st group have had traditional treatment course. This group of animals was control one. Animals of the II-nd group have had the same treatment combined with magnetoacupuncture by alternating magnetic field. We have used a special device for magnetotherapy. One plane magneto was used. Its induction of magnetic field was 30 mT, frequency - 50 Hz. We have stimulated skin in the region of skin projection of acupoints Li4 (hegu) and Li11(quchi) by turns. Acupuncture points localization was determined according to the manual by Chen Jing [3]. We have chosen the mentioned above acupuncture points for stimulation because they represent general acupuncture points with strong vegetation and the Large Intestine Channel of Hand-Yangming is directly connected with zone of traumatized regions of animal mandible. Treatment course consisted of 10 sessions with stimulation of acupoints projection regions during 5 min.

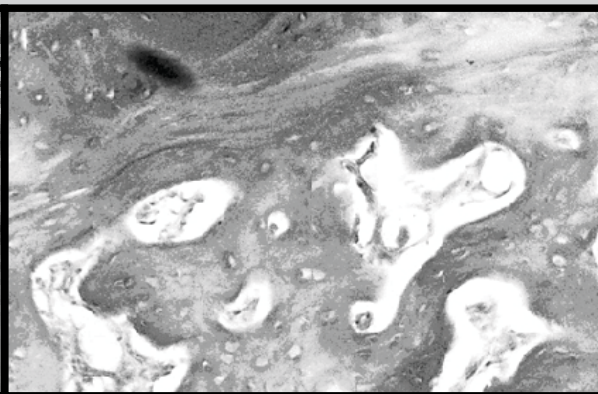
Sampling of materials for morphological tests was performed 7, 14, 21 days and 1, 2 months after the operation. Samples were put in 10% neutral formalin. They were decalcified in nitric acid. According to the general rules samples were processed by spirits of different degree and after that they were put under paraffin. So prepared mounts were paint with hematoxyline-eosine and by Van-Guison's method. Prepared samples were examined by microscope.

### Results

After having examined morphological characteristics of the reparative process of bone tissue of mandible in I and II groups of animals, we have seen that terms of traumatic bone regeneration in the II-nd group of animals have been shorter. During examination with microscope of the samples of the animals which were subjected under magnetoacupuncture course, taken 7 days after the operation, we have seen insignificant difference with control group of animals. Regarding the periosteum, there no proliferative reaction found. Destructive changes as focus of marrow necrosis and



**FIG.1. Morphological structure of new formed bone tissue, 21 days, animals of the II-nd group. (hematoxyline-eosine. 125x).**



**FIG.2. Morphological structure of new formed bone tissue, 1,5 months, animals of the II-nd group (hematoxyline-eosine, 125x).**

loss of osteocyte in regions near of line of cutting were no so good visible. There was found single and small focuses of hemorrhage in marrow cavities. Haversian canels were no enlarged. They have had ordinary configuration. On the 21 day, collagen fibers with specific cellular composition, typical structures without signs of proliferation and resorption were found for animal of the II-nd group (FIG. 1).

Traumatic defect was completely replaced by newfound bone tissue in the same group in 1,5 months. Bone tissue structure was the same as per mature spongy bone (FIG.2). Group of control where magnetoacupuncture was no applied has achieved the same results only 2 months later.

Having done examinations we have concluded that application of magnetoacupuncture in complex with general treatment can provide the following:

- 1) elimination of reactive inflammation in injured tissues in short terms;
- 2) interruption of purulent-inflammatory complications development;
- 3) osteogenesis of bone tissue activation providing compensatory mechanisms entering which respond for regeneration capacities of the bone tissue and of the human body.

As a result clinically tested consolidation and terms of morphological formation of new-formed bone tissue of mandible for animals of the 2-nd group have place earlier to compare with control group what has scientific and practical sense.

## Conclusion

Magnetoacupuncture application (one of the method of acupuncture) in complex with standard treatment of traumatic injuries of bone tissue of mandible is effective and pathogenetically grounded.

## References

- [1] Barkov A.V. Treatment of disorders of reparative regeneration long bones fractures //Orthopedy, traumatol. and prosthesis.- 2000.- №2.- P.94 - 95.
- [2] Bernadskiy Y.I. Traumatology and reparative cranio-maxillofacial surgery.- M.: Medical litterature, 1999.- 456 p.
- [3] Chen Jing. Anatomical atlas of chinese acupuncture points.- Jinan, China: Shandong science and technology press.- 1990.- 266 p.
- [4] Laing A.J., Mullett H., Gilmore M.F. Acupuncture-associated arthritis in a joint with an orthopaedic implant //J. Infect.- 2002.- Vol.44, №1.- P. 43 - 44.
- [5] Musin N.O., Mamontov V.I., Nemsadze V.P. etc. Expierance of electroacupuncture anaesthesia application in orthopedy traumatic practice for children// Orthopedy, traumatology, prosthesis.- 1980.- №6.- P. 41 - 43.
- [6] Ogundare B.O., Bonnick A., Bayley N. Pattern of mandibular fractures in an urban major trauma center //J. Oral. Maxillofac. Surg.- 2003.- Vol.61, №6.- P. 713 - 718.
- [7] Pohodenko-Chudakova I.O., Bezzubik S.D. Acupuncture influence on the regeneration of the traumatic fractures of bone tissue of mandible in experiment// Collection of scient. art. Of republ. scient. conf. «Actual problems of medicine», 15 scient. session of Gomel state medical university. Gomel: GGMU, 2005.- V.3.- Issue 6.- P. 89 – 90.