

ALEKSANDRA KAWALA-STERNIUK, DARIUSZ MIKOLAJEWSKI,
ANNA BRYNIARSKA, MARIA MYSLICKA,
DAMIAN CZARNECKI, ANNA JUNKIERT-CZARNECKA,
ADAM SUDOL, EMILIA MIKOLAJEWSKA,
MATEUSZ PAWLOWSKI, ANNA WŁODARCZYK,
PIOTR WALECKI, RAFAL GASZ,
WITOLD LIBIONKA, BARTOSZ PANCZYSZAK,
MARIUSZ PELC, JAROSLAW ZYGARLICKI,
HENRYK RACHENIUK, KATARZYNA BOJKOWSKA-OTREBSKA,
PIOTR STERNIUK, EDWARD JACEK GORZELANCZYK,
RAFFAELE FERRI

SURVEY ON THE MOST CURRENT IMAGE PROCESSING METHODS IN HUNTINGTON'S DISEASE DIAGNOSTICS AND PROGRESSION ASSESSMENT

Abstract *Huntington's disease (HD) is a rare, incurable neurodegenerative disorder where fast and non-invasive diagnosis targeting patients' condition plays a crucial role. In modern medicine, various scientific areas are being combined, such as computing, medicine and biomedical engineering. This survey is focused on the most recent image processing methods applied not only for the purpose of diagnosing HD but also for the assessment of its progression severity, in order to contribute to the effort to prolong life of and to improve its quality.*

Keywords image processing, Huntington's disease, diagnostics

Citation Computer Science 24(4) 2023: 567–588

Copyright © 2023 Author(s). This is an open access publication, which can be used, distributed and reproduced in any medium according to the Creative Commons CC-BY 4.0 License.

1. Introduction

Huntington's disease (HD) is a rare, incurable neurodegenerative disorder [31, 40, 89] named after George Huntington who reported it for the first time in 1872 [5, 28, 55, 59]. Initially the disease was named Huntington's Chorea. The first cases, however, were clearly described by John Eliotson in 1932 and the first paper concerning HD was published in 1942 by Charles Waters [5].

As mentioned above, HD is a neurodegenerative disorder associated with motor, psychiatric and cognitive disabilities [16, 19, 26, 40, 52, 66, 89]. It is caused by a cytosine-adenine-guanine (CAG) trinucleotide repeat expansion in the huntingtin (HTT) gene, which results in a mutant huntingtin (mHTT) protein with an abnormally long polyglutamine repeat production [26, 55, 69, 82]. It is a single-gene disorder [59]. Most symptoms develop during adulthood [82]. It is clinically characterised with impaired voluntary movements, onset of chorea (involuntary "choreoathetoid" movements), dystonia myoclonic jerks and ticks, and some psychiatric symptoms (anxiety, apathy, sleep problems, depression) [5, 26, 28, 52, 66]. Motor symptoms are the most characteristic symptoms for the HD – chorea, which can cause problems with writing, eating, walking and balance maintenance. The chorea can progress from occasional face twitches to large, strong whole body movements. Motor-related symptoms can be influenced by other conditions such as mental deterioration (stress and/or anxiety) or physical conditions, e.g. infection [28]. Some impairments in several visual domains have been also reported in HD patients such as among others visual object perception, facial emotion recognition, visual working memory or visuo-spatial processing [66]. In pre-manifest HD neither depression nor anxiety occur [28].

The HD causes progressive striatum neuronal degeneration [26]. In the early stages of the disease progressive structural changes in the posterior cerebral cortex can be detected, while frontal and temporal brain regions are less affected [16]. It is also possible to notice mutant huntingtin expression in high cerebral white matter, which may indicate an important role of white matter degeneration in clinical symptoms [52, 66]. White matter loss is considered to be more highly associated with cognitive impairment, which suggests particular importance for its integrity in the HD clinical manifestations [52]. The HD-affected brain is also usually affected by neurodegeneration of caudate and putamen (its atrophy [75]; moreover, widespread neuronal loss in the cortex and other brain regions have also been reported [40, 52, 66, 72].

There are no efficient treatments for this diseases, therefore biomarkers (observed in e.g. MRI images) may help not only to diagnose, but also to monitor progress of this condition [19, 40, 89]. Ultimately, the only way to help patients with the HD is to apply only symptomatic therapies in order to manage and/or minimize their physical and/or mental symptoms [19]. Most of the clinical symptoms usually occur between 30 and 50 years of age [20, 59, 76]. Typical life duration from the first diagnosis to death is between 15 and 20 years [28, 52, 59, 76]. People affected with HD most frequently die because of pneumonia, cardiovascular diseases, injuries due to falls, respiratory disorders and suicide (the second most common cause of death) [1, 11, 28, 59, 76]. The

age of death has been stable for the past 30 years. Also, no gender-related differences have been found in the age of death, which proves that females affected with HD have a larger loss of years [76].

In the Western population HD occurs in 4 – 13.7 individuals per 100,000 [28,55]; however, the most recent UK studies suggest the number to be 12.3/100,000 [28]; Japan, Taiwan and Hong Kong have a much lower incidence of HD of 1–7 per million [28, 55, 59, 65]. One of the highest rates can be observed in Venezuelan communities living near the edge of Lake Maracaibo with the prevalence of 700 in 100,000 people [28]. On the other hand, in South Africa it is possible to observe the disease affects less the black population than the white and mixed ones, which may be related to the differences in the HTT gene [55]. It is said that it affects mostly people of Northern-European origin [59].

Although it is considered as a generic disorder, 6–8% of patients with newly diagnosed HD have no family history, which may either indicate de novo mutations (intermediate length alleles, sporadic cases), non-paternity, misdiagnosis in prior generations, or family members' deaths prior any symptoms occurrence [28]. It is also important to consider that HD has impact not only on people directly affected with it but also on their living environment, families and friends [28, 52, 55, 76]. As it progresses, there is a need for a long or even 24 hour care [55]. Also, many people with HD commit suicide, with a risk estimated to be from 2 to 7 times greater than in general population [5, 12, 19, 21, 22, 25, 77]. It is suggested that the risk of suicide in HD is related to the fact that the disease is neurodegenerative, progressive, seriously hampering functioning in many areas of the patient's life, with the awareness of the lack of effective treatment, and on the other hand, suicidal behavior is not related to perseverative behavior [19, 24, 64].

This survey is focused on the implementation of modern image processing techniques and their description for both, diagnosis and assessment of progression of HD. This is because HD, like almost any other neurodegenerative disease, is at mostly prone to therapy in a very early pre-clinical stage. As such methods (diagnostics) can be considered among the others fully automated structural MRI classification methods, which enable subtle neurodegenerative changes detection [43]. Imaging techniques could be considered biomarkers, which may enable disease progression tracking and efficiency estimation of applied therapies. For the purpose of prevention or delaying neurodegeneration in premanifest patients, appropriate biomarkers may play a very important role [28].

2. State of the art – neuroimaging techniques

The use of medical imaging for diagnostics purposes in clinical practice has a very long history. It helps medical professionals to make the diagnostic and, later, the treatment process more efficient and also allows automated detection, which eases the whole process [43]. These processes are called computer aided detection (CADx) and computer aided diagnosis (CAD) [3].

As no cure has yet been found for neurodegenerative diseases such as HD, it is essential and beneficial for the therapeutic success to recognise and implement the correct therapy in the right patient at the right time. The technical support of clinical practice, especially on the side of diagnostic imaging and the associated computational analysis of large image data-sets is very important here. The number of publications on HD in the PubMed database between 1949 and 2022 reached 14,504 and is growing rapidly since the early 1980s, but only 1,538 of these (10.6%) were about medical imaging in HD, and only 664 of these (4.58%) were about the use of Artificial Intelligence (AI) for the diagnosis and treatment. Thus, an urgent need is evident to intensify the efforts of scientists, engineers and clinicians to improve this situation [6,49]. This is fostered by current trends in the development of eHealth, but also in preventive medicine, personalised medicine and precision medicine, aimed at the development of Clinic 4.0 – medical equivalent of Industry 4.0.

Analysis of brain MRI images requires thorough knowledge of image processing techniques and computer vision together with some fundamentals regarding disease symptoms [67], it is because the MRI-based biomarkers can be particularly promising in HD due to their relative ease of use, cost-effectiveness and non-invasiveness. Research to measure resting functional connectivity of MRI has become increasingly common in recent years and is well established in neuroscience and clinical research in neurodegenerative disorders. However, this is especially true of Alzheimer's disease (AD) and Parkinson's disease (PD), whilst research in HD is limited, hence no definite conclusions can be drawn [36,41].

In addition to more studies in HD, improved classification methods and for the identification of changes in the resting network are needed, more sensitive than those currently available and able to trace disease progression and the impact of therapeutic interventions [39].

The non-invasiveness of MRI and the ability to use MRI to detect specific biomarkers of neurodegenerative diseases such as HD provide a basis for early diagnosis, prevention and treatment of the causes of neurodegenerative diseases, rather than just counteracting their symptoms [49]. The scientific and clinical problem is to find markers reflecting very early lesions starting decades before the onset of clinical symptoms.

Numerous image processing-based methods are currently being applied for the diagnosis and assessment of progression of HD [20,40]. Usually, imaging techniques are applied to find biomarkers for HD, in particular for its pre-manifest stage (preHD). Despite rapid medicine development, neither cure nor therapy for this disease are available [5,20]; therefore, finding appropriate biomarkers plays crucial role at the preHD stage in order to make the potential symptomatic treatment more efficient and to improve life quality of affected persons [20].

The most common HD diagnostics route is genetic testing, HD diagnostics is usually carried out with the use of prenatal genetic tests, which can be carried out typically during 11–13th pregnancy week [28,59,65].

To the most popular imaging methods belong: structural magnetic resonance imaging (MRI), diffusion tensor imaging (DTI), functional MRI (fMRI), computed tomography (CT) and positron emission tomography (PET), F-fluorodeoxyglucose (FDG)–PET, magnetic resonance spectroscopy (MRS) [1,20,28,67]. In this paper the Authors focused on their detailed presentation with some of the most interesting studies involving these methods based on Authors' subjective choice, as it would be impossible to mention and describe all studies on HD involving neuroimaging.

In Figure 1 various brain-imaging methods are presented.

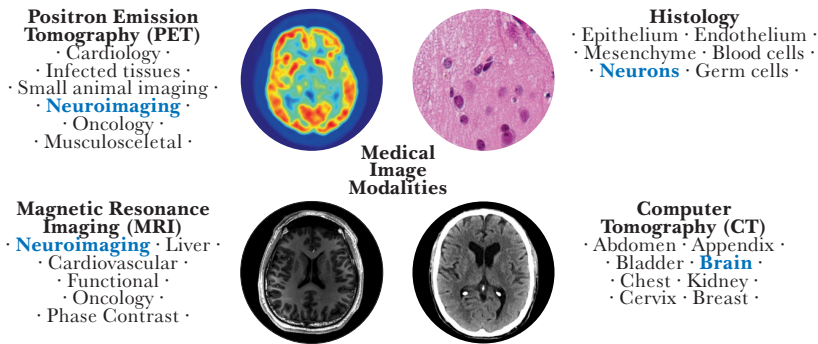


Figure 1. Various brain-imaging techniques [33, 44, 73]

Some of the most powerful tools applied for the assessment of progression of pathology since its pre-manifest stage are neuroimaging techniques such as among others, structural magnetic resonance imaging (MRI), which is a non-invasive technique used for studying structural and micro-structural changes in pre-manifest and manifest HD gene carriers [20, 40, 67]. Structural MRI is one of the most widely studied imaging techniques for the diagnosis and assessment of HD [55]. MRI is useful for the diagnosis of HD as it allows to see some brain-changes related to this disorder, even before its clinical manifestation, such as changes in brain volume and its connectivity, which are visible on MRI-images several years before the HD clinical manifestation. It also enables differentiation of HD from other disorders [1]. MRI devices use strong magnets and radio waves in order capture particular body parts enabling to show tissue anomalies. They provide a great amount of information and enable three-plane visualisation: axial, sagittal and coronal. For the visualisation purposes, water molecules of the examined tissue and the magnetization properties of cell nuclei are used [67].

Structural MRI changes in HD are observed, as well as the association between atrophy, white matter structural changes, iron deposition and clinical outcomes [86].

One interesting method for the diagnosis of HD in its early stage based on MRI, is the Brain Age Estimation (BAE). Indeed, HD may have such an effect on some

brain structures making them seem older. Various machine-learning (ML) and MRI pre-processing methods are used for MRI-based BAE [67].

Functional MRI (fMRI) also enables showing abnormalities in either the pre-manifest or manifest disease stages [20, 23, 28, 55]. It is very useful in assessing alteration in brain functions, in particular using task-based and resting-state fMRI examination [16].

In one study [16] the authors used task-based and resting-state fMRI in order to assess changes in BOLD (blood oxygen level-dependent) signals as a reaction to visual stimulus. Additionally, brain functions in resting-state were examined using functional connectivity analysis. In order to determine cortical changes in the visual cortex, cortical thickness of eight regions was examined (cuneus, fusiform gyrus, inferior temporal cortex, lateral occipital cortex, lingual gyrus, pericalcarine cortex, superior parietal cortex, and temporal pole). As a result, a significant cortical thinning was observed in patients with manifest HD, while the pre-manifest HD patients did not have any significant changes in cortical thickness. The authors evaluated their results using voxel-based morphometry (VBM) analysis.

VBM analysis is a very interesting method applied in various neurodegenerative disorders and can be treated as a biomarker. Its advantage is that it is automated and easy to use and to apply for user-specified testing. The weakness of the method is that biological differences can appear similar, depending on images obtained in various ways and various types of corrections applied, which may lead to misinterpretations of the results. This is because of the uniformity lack for this method [37].

Contrary to the above study [16], where it was stated that fMRI should not be considered as a biomarker in preHD patients, the authors of another report [23] showed that some fMRI activation in the right-frontal oculomotor cortex could be efficiently considered as a biomarker also in preHD patients.

A very interesting MRI technique is the diffusion-weighted imaging (DWI), which is usually applied for the purpose of in vivo water diffusion measurement and its application in brain imaging relies on providing information about the white matter fibre tracts microstructure (also in the pre-manifest stage) [55]. The technology on which DWI is based is a powerful technique for inferring local fiber orientation of fiber bundles, which enables the reconstruction of major pathways in the brain [66]. Interesting imaging method is a diffusion tractography for automated reconstruction of eighteen major cerebral WM fiber bundles entitled TRActs Constrained by UnderLying Anatomy (TRACULA), as described by Rosas et al. [66]. Their method applies global probabilistic tractography with anatomical priors. The TRACULA allows quantification of the white matter differences in a very great detail, which improves potential diagnosis of HD. The reported results were promising.

Another diffusion-based technique is diffusion tensor imaging (DTI), where the diffusion process orientation dependence is measured. It relies on diffusion-induced MRI signal loss as a function of diffusion-weighting gradient orientations and enables the characterisation of the diffusion tensor at each spatial location [17, 45, 47, 81]. It

also provides numerous parameters describing various aspects of the diffusion of biological processes and also enables to reveal specific tissue structures such as among others, white-matter fiber tracts to detect their changes during particular disease progression or regression [17, 45, 47, 81]. It can be applied in the diagnostic process of various disorders, such as cerebral ischemia, multiple sclerosis, epilepsy, metabolic disorders, and brain tumors [17]. The diffusion tensor imaging was used by Magnotta and his colleagues in their work [52] in order to analyse white matter changes associated with HD development. They cross-sectionally imaged 31 pre-clinical gene-mutation carriers using diffusion tensor and anatomical brain imaging of patients with a known HD gene mutation but without visible characteristic motor manifestation. As a result, they reported a positive correlation with a 5-year diagnosis probability in the putamen and a negative correlation in the external capsule, showing that diffusion tensor imaging-generated scalar maps can be correlated with the very early stage of HD and could be considered a bio-marker for the disease progression in pre-manifest patients. Additionally, DTI has been also applied in other studies on various brain diseases, such as Alzheimer's disease (AD), mild cognitive impairment (MCI), multiple sclerosis (MS), traumatic brain injury, and schizophrenia, etc. [45, 52].

Myelin water imaging (MWI) in HD can detect and quantify changes not observed with conventional medical imaging, and reduced myelin content may be associated with lower cognitive performance and poorer clinical presentation. MWI thus provides insights into the pathophysiology and disease mechanisms of various neurodegenerative syndromes [6].

PET imaging in HD uses radioactive tracers to detect changes at the molecular level that could be used as markers of HD progression and to monitor treatment response in HD gene expression carriers (HDGECs): changes in postsynaptic dopamine receptors, cannabinoid, adenosine and GABA receptors, histamine and serotonin receptors, brain metabolism, microglia activation, phosphodiesterase 10A (PDE10A) [85] supported by plasma cytokines (small molecule p75^{NTR} prototype of the ligand LM11A-31) [74]. PET with the use of phosphodiesterase 10A tracer enables detecting changes in preHD up to 25 [55] or even 43 [85] years before clinical symptoms or even before the occurrence of white and grey matter changes [78].

2.1. Artificial intelligence, machine learning and deep learning

The above-mentioned MRI-based BAE method is formed on the two following factors: methods for MRI images processing (pixel-based, surface-based, or voxel-based); generation of the applied machine learning (ML) algorithms (traditional or deep learning (DL) methods) [50, 67, 75]. They allow to differentiate between typical and atypical aging of the brain since physical (real) age and predicted brain age may differ [51, 93]. Basodi et al. [7] proposed a decentralized method of estimating MRI-BAE using SVM regression models. It has been evaluated on three different sets of characteristics (volumetric and voxel MRI structural data, resting MRI functional data). The key problem is that some DL models for temporal regression apply for estimation only

single input images instead using relationships between different images [34]. Zhang et al. [93] combined efficiently four DL algorithms: SVM, CNN, GoogLeNet, and ResNet so this computational problem can be considered complex, but close to the solution.

The modern techniques, to which DL methods belong, allow to obtain more accurate results. Recent rapid development of ML algorithms simplified the accuracy and improved the results [67]. Applying ML algorithms to large data-sets (3158 patients, 44 motor, cognitive, and functional parameters) in HD showed that its onset can be divided into nine identified disease states: 1–2 (early disease): 16 years, 3–5 (transition): 10 years, 6–9 (late disease): 10 years [58].

Image analysis relies on extracting appropriate information from images in an efficient way in order to improve the clinical diagnosis process. For this purpose various ML-based techniques are being developed [2, 3, 8, 9, 14, 57]. DL-based methods such as neural networks are used for automated feature learning [3, 9, 15, 27, 53, 62], contrary to traditional methods, where both appropriate features selection and calculation are a very challenging task [3, 9, 46, 70, 87].

DL analysis methods are frequently applied in various scientific areas such as computer vision, speech analysis, and natural language processing (NLP). They are usually efficient in areas where a large amount of data is analysed [3, 56, 90]. They also mimic human brain and human-like intelligence [3] including a variety of image recognition and diagnostic tasks. Such AI-based models already have an accuracy of over 90% [84], but it is worth making efforts to increase the dynamics and systematicity of research reports on diagnostic applications of AI. This can help to increase the efficiency of clinical procedures and thus relieve the healthcare system.

Out of various DL techniques applied for biomedical images analysis – deep convolutional networks (DCN) are one of the most frequently used techniques [3, 32, 68]. DCNs are usually applied for: segmentation abnormality detection, disease classification, computer aided diagnosis and retrieval [3]. Commonly used neural network architectures have many optimizable parameters, and finding the best configuration for them often means higher computational costs [88], so further interdisciplinary research is needed into solutions that are fast, but cheap at the same time, and can be used in clinical practice on a daily basis.

The use of AI solutions to analyze small data-sets from medical research is a relatively new concept that has been more intensively used in the last 5 years, despite the fact that the first publications on AI analysis of small data-sets are over 20 years old. It has been assumed that traditional neural networks, as a data-driven method in ML, are useful for the analysis of big data, e.g. for automatic rule extraction, classification and prediction, also within hierarchical fuzzy systems. But it has long been known that the medical sciences and health rarely have large, homogeneous data, and are subject to more complexity than in any other scientific discipline. Pace et al. [61] successfully conducted research on the segmentation of medical MRI images in a group of 20 patients with congenital heart disease (CHD) using recursive neu-

ral networks. Similar results were achieved by Henderson et al. [35] in AI-supported oncology CT analysis in 35 patients. AI-based analysis of small imaging data-sets allows to introduce truly preventive medicine and personalized therapy in rare diseases, including HD.

Multifractal analyses, especially fractal dimension (FD) are finding applications in the search for sensitive and specific biomarkers of neurodegenerative diseases and dementia for diagnosing the disease and tracking its progression [4, 54, 91, 94]. Neurodegenerative disease processes are usually associated with a decrease in the FD of the brain observed independently of atrophy. A barrier to the wider application of FD in HD is the non-specific complex temporal and spatial patterns. Technical factors related to image processing and FD measurement are key to advancing diagnostics. Belonging to multi-fractal analysis, the Hurst exponent allows the possibility of trend reversal (e.g. therapy-induced reversal) to be identified [4, 91].

Fuzzy methods also have similar predictive power, in particular (for cyclic measurements at multiple time points) directed fuzzy numbers, where the direction of change is important [94].

3. Summary and conclusions

A summary of the current knowledge and experience, including a literature review, points to the need for a deeper exploration of medical images and AI-based HD biomarkers. HD as a rare disease seems to be beyond the focus of the largest projects and research group dealing with IT support in medical imaging, so such reviews are very important both to summarize current knowledge and experiences and to stimulate further research.

This work presents a detailed review of the current method involving medical image analysis, which could have significant impact on clinical diagnosis. In Table 1, a summary of these methods is presented.

Table 1
Summary of the described methods

Method	Description
Deep learning (DL) methods [38, 79, 92]	Deep learning methods use artificial intelligence (AI) algorithms; Commonly used in various types of automatic recognition of objects and textures.
Convolutional Neural Networks (CNN) [48, 92]	CNNs are based on deep machine learning (DL) techniques, which are widely used in many research domains such as computer vision, speech analysis and natural language processing. A very efficient and discriminant method, but requires a very well-defined training set. CNNs can be used in scene analysis in various analytical techniques.

Table 1 cont.

Method	Description
Magnetic Resonance Imaging (MRI) [6, 48, 63]	MRI is a medical imaging technique that obtains an image of the inside of a patient's body without disturbing any tissue, which makes it an important tool in the diagnosis of many diseases; It detects the resonant frequency of water molecules in the human body. Magnetic resonance images can have a spatial resolution of as much as 50 ppi. Due to its non-invasiveness, it is very well suited for imaging the brain in Huntington's disease.
Positron Emission Tomography (PET) [13, 29, 71]	PET is a medical imaging technique, which obtains an image of the radiation generated during positron annihilation. The biggest disadvantage of this method is the need to administer an isotope with a half-life of 110 mins to the patient. The method works very well in the diagnosis of neoplasms, but from the point of view of HD diagnostics, it is of limited applicability.
Histology [60, 83]	Histology is a technique of microscopic imaging of tissues, which is not relevant for the diagnosis of HD in alive patients due to the way the samples are prepared. The examined tissues are frozen and then cut into very thin layers, which are first photographed.
Computer Tomography (CT) [48, 71]	CT is a medical imaging technique using X-rays, which enables to obtain a precise and multi-layered image of the brain and its cranio-facial area. As the CT requires a greater dose of radiation than conventional radio-logical examinations such as X-rays, there are many contraindications to the use of this medical imaging technique.

Figure 2 shows what the detection of the edges of the affected areas of the brain images looks like on MRI.

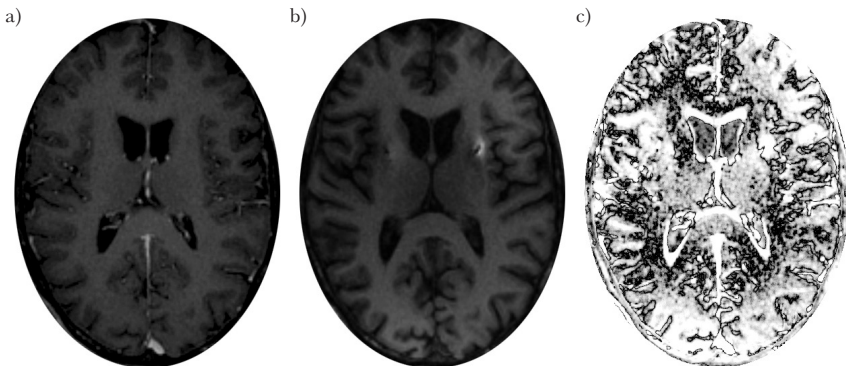


Figure 2. MRI of the patient's brain before implantation (a), after implantation (b) and differences in brain images (c)

Figure 2c shows the marked (black outline) areas where changes have occurred in the brain. Such an image will then be segmented in order to determine the parameters of the changes based on the morphological parameters of the individual segments in the image.

3.1. Limitations of the current approaches

The current limitations of image processing methods in the diagnosis and assessment of HD progression are the rarity of its occurrence and, consequently, the small databases of HD patients managed over long periods of time (multiple measurement points) with the same research and clinical methodology, the limited capacity of multidisciplinary teams such as the team of authors of this article, and the lack of time and financial capacity to test all available computing technologies on the same groups of patients in order to select optimal diagnostic and therapeutic approaches. In the era of preventive medicine, personalised medicine and precision medicine, healthcare units should be prepared to take action (monitoring, detailed diagnosis, therapy) at the earliest possible stage on the basis of a mere prediction of the risk of developing a condition; meanwhile, at present, they often end up diagnosing the absence of a full set of clinical symptoms and moving on to periodic follow-ups with the assumption that clinical symptoms will one day occur.

Treatment of neurodegenerative diseases is one of the key problems of modern society and probably most beneficial in the very early, perhaps pre-clinical stages of degeneration. In this paper, we have shown the usefulness of methods based on image analysis for detecting degenerative changes characteristic of HD. Such methods in combination with min. The availability of a Huntington's disease (HD) genetic test could be an excellent metric for the earliest diagnosis, as well as for assessing the effectiveness of using image-only methods in asymptomatic carriers of gene mutations [43].

The method shown in Fig. 1 is based on the detection of differences between images of the same area of the brain at given intervals. However, repeatable acquisition of brain MRI images in HD patients is extremely difficult. Patients with movement disorders such as HD are unable to stay in one position for long periods. It is impossible to acquire an MRI of the brain of an HD patient with exactly the same angular distortion every time. The patient's head can be tilted forward, backward or sideways, which will cause the images of the individual layers to be taken with different angular distortions. Therefore, it seems that the best way to segment MRI images is to segment the entire "stack" of images. This approach will result in a spatial image (3D) of the selected brain segment. By using a sensitive differential mechanism, i.e. Hilbert transforms [30], it will be possible to detect small changes in the shape of the segmented areas.

3.2. Potential further research paths

The aim of future research should be define approaches using medical imaging applied to HD, taking into account the main determinants of research efficiency: character-

istics and homogeneity of the study and control group, structural versus task-based functional neuroimaging (including fMRI); simultaneous fMRI and EEG, resting-state networks, HD risk biomarkers, biomarkers of HD symptom severity, predictors of treatment response and prognosis, efficient computational analysis, including fuzzy and multi-fractal-based analysis. To achieve this, access to large structured databases of HD patient outcomes and large interdisciplinary research projects using prototype AI-based technologies are key.

There are still many unproven solutions in the field of artificial intelligence that can aid HD image-based diagnostics. These include fuzzy models, but also a wide range of biocybernetic and neurocybernetic models of the brain, ranging from fluid models to biologically accurate models based on Hodgkin-Huxley point and compartmental neurons [18]. Artificial intelligence in image analysis for the needs of early HD diagnostics is still waiting for new discoveries.

An alternative approach to image processing may also be based on template matching [80]. This technique uses an image fragment (patch) which may represent e.g. a degenerated/symptomatic fragment of a tissue and is trying to find such a match in a reference image. Originally, this method was widely used for features extractions purposes [42], but recently template matching is being successfully applied to computer vision [10] where, as such, it may greatly contribute to develop innovative tools and techniques for diagnostic purposes.

References

- [1] Ajitkumar A., De Jesus O.: *Huntington Disease*, StatPearls Publishing, 2021.
- [2] Anwar A., Iqbal A.: Image processing technique for brain abnormality detection, *International Journal of Image Processing*, vol. 7(1), pp. 51–61, 2013.
- [3] Anwar S.M., Majid M., Qayyum A., Awais M., Alnowami M., Khan M.K.: Medical Image Analysis using Convolutional Neural Networks: A Review, *Journal of Medical Systems*, vol. 42(11), pp. 1–13, 2018. doi: 10.1007/s10916-018-1088-1.
- [4] Azizi T.: On the fractal geometry of gait dynamics in different neurodegenerative diseases, *Physics in Medicine*, vol. 14, 100050, 2022. doi: 10.1016/j.phmed.2022.100050.
- [5] Balaban Ö.D., Atbaşoğlu C.E.: Neuropsychiatric Aspects of Huntington's Disease, *Psikiyatride Güncel Yaklaşımlar*, vol. 14(1), pp. 98–112, 2022. doi: 10.18863/pgy.952664.
- [6] Balaji S., Johnson P., Dvorak A.V., Kolind S.H.: Update on myelin imaging in neurological syndromes, *Current Opinion in Neurology*, vol. 35(4), pp. 467–474, 2022. doi: 10.1097/WCO.0000000000001078.
- [7] Basodi S., Raja R., Ray B., Gazula H., Sarwate A.D., Plis S., Liu J., Verner E., Calhoun V.D.: Decentralized Brain Age Estimation Using MRI Data, *Neuroinformatics*, vol. 20, pp. 981–990, 2022. doi: 10.1007/s12021-022-09570-x.

- [8] Beghdadi A., Larabi M.-C., Bouzerdoum A., Iftekharuddin K.M.: A survey of perceptual image processing methods, *Signal Processing: Image Communication*, vol. 28(8), pp. 811–831, 2013. doi: 10.1016/j.image.2013.06.003.
- [9] Bhatt C., Kumar I., Vijayakumar V., Singh K.U., Kumar A.: The state of the art of deep learning models in medical science and their challenges, *Multimedia Systems*, vol. 27(4), pp. 599–613, 2021. doi: 10.1007/s00530-020-00694-1.
- [10] Brunelli R.: *Template matching techniques in computer vision: theory and practice*, John Wiley & Sons, 2009.
- [11] Buyan Dent L., Shannon K.M.: Emergencies in Huntington’s Disease. In: S.J. Frucht (ed.), *Movement Disorder Emergencies*, pp. 531–541, Springer, 2022. doi: 10.1007/978-3-030-75898-1_29.
- [12] Calero M.G.R., Galiano A.B.J.: Neurodegenerative disease and suicide, *Revista Científica de la Sociedad de Enfermería Neurológica (English ed)*, vol. 55, pp. 25–32, 2021. doi: 10.1016/j.sedeng.2021.02.003.
- [13] Carson R.E., Naganawa M., Toyonaga T., Koohsari S., Yang Y., Chen M.K., Matuskey D., Finnema S.J.: Imaging of Synaptic Density in Neurodegenerative Disorders, *Journal of Nuclear Medicine*, vol. 63 (Suppl. 1), pp. 60S–67S, 2022. doi: 10.2967/jnumed.121.263201.
- [14] Cheng J., Liu H.-P., Lin W.-Y., Tsai F.-J.: Machine learning compensates fold-change method and highlights oxidative phosphorylation in the brain transcriptome of Alzheimer’s disease, *Scientific Reports*, vol. 11, 13704, 2021. doi: 10.1038/s41598-021-93085-z.
- [15] Cheng J., Liu H.-P., Lin W.-Y., Tsai F.-J.: Identification of contributing genes of Huntington’s disease by machine learning, *BMC Medical Genomics*, vol. 13(1), 176, 2020. doi: 10.1186/s12920-020-00822-w.
- [16] Coppen E.M., Grond J., van der, Hafkemeijer A., Barkey Wolf J.J.H., Roos R.A.C.: Structural and functional changes of the visual cortex in early Huntington’s disease, *Human Brain Mapping*, vol. 39(12), pp. 4776–4786, 2018. doi: 10.1002/hbm.24322.
- [17] Dong Q., Welsh R.C., Chenevert T.L., Carlos R.C., Maly-Sundgren P., Gomez-Hassan D.M., Mukherji S.K.: Clinical applications of diffusion tensor imaging, *Journal of Magnetic Resonance Imaging: An Official Journal of the International Society for Magnetic Resonance in Medicine*, vol. 19(1), pp. 6–18, 2004. doi: 10.1002/jmri.10424.
- [18] Duch W.: Mind as a shadow of neurodynamics, *Physics of Life Reviews*, vol. 31, pp. 28–31, 2019. doi: 10.1016/j.plrev.2019.01.023.
- [19] Duijn E., van, Fernandes A.R., Abreu D., Ware J.J., Neacy E., Sampaio C.: Incidence of completed suicide and suicide attempts in a global prospective study of Huntington’s disease, *BJPsycho Open*, vol. 7(5), 2021. doi: 10.1192/bjo.2021.969.
- [20] Esmaeilzadeh M., Ciarmiello A., Squitieri F.: Seeking brain biomarkers for preventive therapy in Huntington disease, *CNS Neuroscience & Therapeutics*, vol. 17(5), pp. 368–386, 2011. doi: 10.1111/j.1755-5949.2010.00157.x.

- [21] Fernandez H.H., Factor S.A., Hauser R.A., Jimenez-Shahed J., Ondo W.G., Jarskog L.F., Meltzer H.Y., et al.: Randomized controlled trial of deutetrabenazine for tardive dyskinesia: the ARM-TD study, *Neurology*, vol. 88(21), pp. 2003–2010, 2017. doi: 10.1212/WNL.0000000000003960.
- [22] Fernandez H.H., Stamler D., Davis M.D., Factor S.A., Hauser R.A., Jimenez-Shahed J., Ondo W.G., et al.: Long-term safety and efficacy of deutetrabenazine for the treatment of tardive dyskinesia, *Journal of Neurology, Neurosurgery & Psychiatry*, vol. 90(12), pp. 1317–1323, 2019. doi: 10.1136/jnnp-2018-319918.
- [23] Ferraro S., Nanetti L., Piacentini S., Mandelli M.L., Bertolino N., Ghielmetti F., Epifani F., et al.: Frontal cortex BOLD signal changes in premanifest Huntington disease: a possible fMRI biomarker, *Neurology*, vol. 83(1), pp. 65–72, 2014. doi: 10.1212/WNL.0000000000000538.
- [24] Ferreira J.J., Rodrigues F.B., Duarte G.S., Mestre T.A., Bachoud-Levi A.-C., Bentivoglio A.R., Burgunder J.M., Cardoso F., et al.: An MDS Evidence-Based Review on Treatments for Huntington’s Disease, *Movement Disorders*, vol. 37(1), pp. 25–35, 2022. doi: 10.1002/mds.28855.
- [25] Frank S., Testa C., Edmondson M.C., Goldstein J., Kayson E., Leavitt B.R., Oakes D., et al.: The Safety of Deutetrabenazine for Chorea in Huntington Disease: An Open-Label Extension Study, *CNS Drugs*, vol. 36(11), pp. 1207–1216, 2022. doi: 10.1007/s40263-022-00956-8.
- [26] Georgiou-Karistianis N., Sritharan A., Farrow M., Cunnington R., Stout J., Bradshaw J., Churchyard A., et al.: Increased cortical recruitment in Huntington’s disease using a Simon task, *Neuropsychologia*, vol. 45(8), pp. 1791–1800, 2007. doi: 10.1016/j.neuropsychologia.2006.12.023.
- [27] Ghazaleh N., Houghton R., Palermo G., Schobel S.A., Wijeratne P.A., Long J.D.: Ranking the Predictive Power of Clinical and Biological Features Associated With Disease Progression in Huntington’s Disease, *Frontiers in Neurology*, vol. 12, 678484, 2021. doi: 10.3389/fneur.2021.678484.
- [28] Ghosh R., Tabrizi S.J.: Clinical features of Huntington’s disease. In: C. Nóbrega, L. Pereira de Almeida (eds.), *Polyglutamine Disorders*, pp. 1–28, Springer Cham, 2018. doi: 10.1007/978-3-319-71779-1_1.
- [29] Gündel D., Toussaint M., Lai T.H., Deuther-Conrad W., Cumming P., Schröder S., Teodoro R., et al.: Quantitation of the A_{2A} Adenosine Receptor Density in the Striatum of Mice and Pigs with [¹⁸F]FLUDA by Positron Emission Tomography, *Pharmaceuticals*, vol. 15(5), 516, 2022. doi: 10.3390/ph15050516.
- [30] Hahn S.: *Hilbert Transforms in Signal Processing*, Artech House, 1996.
- [31] Haines J.L., Conneally P.M., Rao D.C.: Causes of death in Huntington disease as reported on death certificates, *Genetic Epidemiology*, vol. 3(6), pp. 417–423, 1986. doi: 10.1002/gepi.137003060.
- [32] Han S., Shi Z., Shi Y.: Cultural and Creative Product Design and Image Recognition Based on the Convolutional Neural Network Model, *Computational Intelligence and Neuroscience*, vol. 2022, 2586042, 2022. doi: 10.1155/2022/2586042.

- [33] Hansson O.: Biomarkers for neurodegenerative diseases, *Nature Medicine*, vol. 27(6), pp. 954–963, 2021. doi: 10.1038/s41591-021-01382-x.
- [34] He S., Feng Y., Ellen Grant P., Ou Y.: Deep Relation Learning for Regression and Its Application to Brain Age Estimation, *IEEE Transactions on Medical Imaging*, vol. 41(9), pp. 2304–2317, 2022. doi: 10.1109/TMI.2022.3161739.
- [35] Henderson E.G.A., Vasquez Osorio E.M., Herk M., van, Green A.F.: Optimising a3D convolutional neural network for head and neck computed tomography segmentation with limited training data, *Physics and Imaging in Radiation Oncology*, vol. 22, pp. 44–50, 2022. doi: 10.1016/j.phro.2022.04.003.
- [36] Henley S.M.D., Bates G.P., Tabrizi S.J.: Biomarkers for neurodegenerative diseases, *Current Opinion in Neurology*, vol. 18(6), pp. 698–705, 2005. doi: 10.1097/01.wco.0000186842.51129.cb.
- [37] Henley S.M.D., Ridgway G.R., Scahill R.I., Kloppel S., Tabrizi S.J., Fox N.C., Kassubek J., Group E.I.W., *et al.*: Pitfalls in the use of voxel-based morphometry as a biomarker: examples from Huntington disease, *American Journal of Neuroradiology*, vol. 31(4), pp. 711–719, 2010. doi: 10.3174/ajnr.A1939.
- [38] Hett K., Giraud R., Johnson H., Paulsen J.S., Long J.D., Oguz I.: Patch-Based Abnormality Maps for Improved Deep Learning-Based Classification of Huntington’s Disease. In: A.L. Martel, P. Abolmaesumi, D. Stoyanov, D. Mateus, M.A. Zuluaga, S.K. Zhou, D. Racoceanu, L. Joskowicz (eds.), *Medical Image Computing and Computer Assisted Intervention – MICCAI 2020*. Lecture Notes in Computer Science, vol. 12267, pp. 636–645, Springer Cham, 2020. doi: 10.1007/978-3-030-59728-3_62.
- [39] Hohenfeld C., Werner C.J., Reetz K.: Resting-state connectivity in neurodegenerative disorders: Is there potential for an imaging biomarker?, *NeuroImage: Clinical*, vol. 18, pp. 849–870, 2018. doi: 10.1016/j.nicl.2018.03.013.
- [40] Johnson E.B., Gregory S.: Huntington’s disease: brain imaging in Huntington’s disease. In: J.T. Becker, A.D. Cohen (eds.), *Chapter 6 – Progress in Molecular Biology and Translational Science*, vol. 165, pp. 321–369, Academic Press, 2019. doi: 10.1016/bs.pmbts.2019.04.004.
- [41] Kandel B.M., Avants B.B., Gee J.C., McMillan C.T., Erus G., Doshi J., Davatzikos C., Wolk D.A.: White matter hyperintensities are more highly associated with preclinical Alzheimer’s disease than imaging and cognitive markers of neurodegeneration, *Alzheimer’s & Dementia: Diagnosis, Assessment & Disease Monitoring*, vol. 4, pp. 18–27, 2016. doi: 10.1016/j.dadm.2016.03.001.
- [42] Kaur A., Jarial E.P.: Object Recognition using Template matching with the help of Features extraction method, *Research Journal of Engineering and Technology (IRJET)*, vol. 2(5), pp. 178–182, 2015.
- [43] Klöppel S., Chu C., Tan G.C., Draganski B., Johnson H., Paulsen J.S., Kienle W., Tabrizi S.J., Ashburner J., Frackowiak R.S.J., *et al.*: Automatic detection of preclinical neurodegeneration: presymptomatic Huntington disease, *Neurology*, vol. 72(5), pp. 426–431, 2009. doi: 10.1212/01.wnl.0000341768.28646.b6.

- [44] Koničková D., Menšíková K., Tučková L., Hényková E., Strnad M., Friedecký D., Stejskal D., Matěj R., Kaňovský P.: Biomarkers of Neurodegenerative Diseases: Biology, Taxonomy, Clinical Relevance, and Current Research Status, *Biomedicines*, vol. 10(7), 1760, 2022. doi: 10.3390/biomedicines10071760.
- [45] Le Bihan D., Mangin J.-F., Poupon C., Clark Ch.A., Pappata S., Molko N., Chabriat H.: Diffusion tensor imaging: concepts and applications, *Journal of Magnetic Resonance Imaging: An Official Journal of the International Society for Magnetic Resonance in Medicine*, vol. 13(4), pp. 534–546, 2001. doi: 10.1002/jmri.1076.
- [46] Lemercier P., Cleret de Langavant L., Hamet Bagnou J., Youssov K., Lemoine L., Audureau E., Massart R., Bachoud-Lavi A.C.: Self-Reported Social Relationship Capacities Predict Motor, Functional and Cognitive Decline in Huntington’s Disease, *Journal of Personalized Medicine*, vol. 12(2), 174, 2022. doi: 10.3390/jpm12020174.
- [47] Lerner A., Mogensen M.A., Kim P.E., Shiroishi M.S., Hwang D.H., Law M.: Clinical applications of diffusion tensor imaging, *World Neurosurgery*, vol. 82(1–2), pp. 96–109, 2014. doi: 10.1016/j.wneu.2013.07.083.
- [48] Li H., Zhang H., Johnson H., Long J.D., Paulsen J.S., Oguz I.: MRI subcortical segmentation in neurodegeneration with cascaded 3D CNNs. In: I. Išgum, B.A. Landman (eds.), *Medical Imaging 2021: Image Processing*, 115960W, 2021. doi: 10.1117/12.2582005.
- [49] Li K.R., Wu A.G., Tang Y., He X.P., Yu C.L., Wu J.M., Hu G.Q., Yu L.: The Key Role of Magnetic Resonance Imaging in the Detection of Neurodegenerative Diseases-Associated Biomarkers: A Review, *Molecular Neurobiology*, vol. 59, pp. 5935–5954, 2022. doi: 10.1007/s12035-022-02944-x.
- [50] Litjens G., Kooi T., Bejnordi B.E., Setio A.A.A., Ciompi F., Ghafoorian M., Laak J.A.W.M., van der, Ginneken B., van, Sánchez C.I.: A survey on deep learning in medical image analysis, *Medical Image Analysis*, vol. 42, pp. 60–88, 2017. doi: 10.1016/j.media.2017.07.005.
- [51] Liu X., Beheshti I., Zheng W., Li Y., Li S., Zhao Z., Yao Z., Hu B.: Brain age estimation using multi-feature-based networks, *Computers in Biology and Medicine*, vol. 143, 105285, 2022. doi: 10.1016/j.compbimed.2022.105285.
- [52] Magnotta V.A., Kim J., Kosciak T., Beglinger L.J., Espinso D., Langbehn D., Nopoulos P., Paulsen J.S.: Diffusion tensor imaging in preclinical Huntington’s disease, *Brain Imaging and Behavior*, vol. 3(1), pp. 77–84, 2009. doi: 10.1007/s11682-008-9051-2.
- [53] Maier A., Syben C., Lasser T., Riess C.: A gentle introduction to deep learning in medical image processing, *Zeitschrift für Medizinische Physik*, vol. 29(2), pp. 86–101, 2019. doi: 10.1016/j.zemedi.2018.12.003.

- [54] Marzi C., Giannelli M., Tessa C., Mascalchi M., Diciotti S.: Toward a more reliable characterization of fractal properties of the cerebral cortex of healthy subjects during the lifespan, *Scientific Reports*, vol. 10(1), 16957, 2020. doi: 10.1038/s41598-020-73961-w.
- [55] McColgan P., Tabrizi S.J.: Huntington's disease: a clinical review, *European Journal of Neurology*, vol. 25(1), pp. 24–34, 2018. doi: 10.1111/ene.13413.
- [56] Meng Y., Zhang J.: An effective behavior recognition method in the video session using convolutional neural network, *PLoS One*, vol. 17(8), e0266734, 2022. doi: 10.1371/journal.pone.0266734.
- [57] Mestre T.A.: Using Big Data in Movement Disorders: Disease States and Progression in Huntington's Disease, *Movement Disorders*, vol. 37(3), pp. 441–443, 2022. doi: 10.1002/mds.28943.
- [58] Mohan A., Sun Z., Ghosh S., Li Y., Sathe S., Hu J., Sampaio C.: A Machine-Learning Derived Huntington's Disease Progression Model: Insights for Clinical Trial Design, *Movement Disorders*, vol. 37(3), pp. 553–562, 2022. doi: 10.1002/mds.28866.
- [59] Novak M.J.U., Tabrizi S.J.: Huntington's disease: clinical presentation and treatment, *International Review of Neurobiology*, vol. 98, pp. 297–323, 2011. doi: 10.1016/B978-0-12-381328-2.00013-4.
- [60] Olesen M.A., Villavicencio-Tejo F., Quintanilla R.A.: The use of fibroblasts as a valuable strategy for studying mitochondrial impairment in neurological disorders, *Translational Neurodegeneration*, vol. 11(1), 36, 2022. doi: 10.1186/s40035-022-00308-y.
- [61] Pace D.F., Dalca A.V., Brosch T., Geva T., Powell A.J., Weese J., Moghari M.H., Golland P.: Iterative Segmentation from Limited Training Data: Applications to Congenital Heart Disease. In: D. Stoyanov, *et al.* (eds.), *Deep Learning in Medical Image Analysis and Multimodal Learning for Clinical Decision Support. DLMIA ML-CDS 2018*, Lecture Notes in Computer Science, vol. 11045, pp. 334–342, Springer, Cham, 2018. doi: 10.1007/978-3-030-00889-5_38.
- [62] Razzak M.I., Naz S., Zaib A.: Deep Learning for Medical Image Processing: Overview, Challenges and the Future. In: N. Dey, A.S. Ashour, S. Borra (eds.), *Classification in BioApps: Automation of Decision Making*, pp. 323–350, Springer, Cham, 2018. doi: 10.1007/978-3-319-65981-7_12.
- [63] Rocha N.P., Charron O., Colpo G.D., Latham L.B., Patino J.E., Stimming E.F., Freeman L., Teixeira A.L.: Cerebral blood flow is associated with markers of neurodegeneration in Huntington's disease, *Parkinsonism & Related Disorders*, vol. 102, pp. 79–85, 2022. doi: 10.1016/j.parkreldis.2022.07.024.
- [64] Roman O.C., Stovall J., Claassen D.O.: Perseveration and Suicide in Huntington's Disease, *Journal of Huntington's Disease*, vol. 7(2), pp. 185–187, 2018. doi: 10.3233/JHD-170249.
- [65] Roos R.A.C.: Huntington's disease: a clinical review, *Orphanet Journal of Rare Diseases*, vol. 5(1), 40, 2010. doi: 10.1186/1750-1172-5-40.

- [66] Rosas H.D., Wilkens P., Salat D.H., Mercaldo N.D., Vangel M., Yendiki A.Y., Hersch S.M.: Complex spatial and temporally defined myelin and axonal degeneration in Huntington disease, *NeuroImage: Clinical*, vol. 20, pp. 236–242, 2018. doi: 10.1016/j.nicl.2018.01.029.
- [67] Sajedi H., Pardakhti N.: Age Prediction Based on Brain MRI Image: A Survey, *Journal of Medical Systems*, vol. 43(8), 279, 2019. doi: 10.1007/s10916-019-1401-7.
- [68] Sassi A., Ouarda W., Amar C.B.: Deep Content Information Retrieval for COVID-19 Detection from Chromatic CT Scans, *Arabian Journal for Science and Engineering*, vol. 48, pp. 1935–1945, 2022. doi: 10.1007/s13369-022-07083-y.
- [69] Saudou F., Humbert S.: The Biology of Huntingtin, *Neuron*, vol. 89(5), pp. 910–926, 2016. doi: 10.1016/j.neuron.2016.02.003.
- [70] Schneider P., Węjcik G.M., Kawiak A., Kwasniewicz L., Wierzbicki A.: Modeling and Comparing Brain Processes in Message and Earned Source Credibility Evaluation, *Frontiers in Human Neuroscience*, vol. 16, 808382, 2022. doi: 10.3389/fnhum.2022.808382.
- [71] Schroeter T., Gühne F., Schwab M., Drescher R., Axer H.: Differentiation of Reversible Hemichorea Due to Vitamin B12 Deficiency From Huntington Disease Via FDG PET, *Clinical Nuclear Medicine*, vol. 47(9), pp. 830–831, 2022. doi: 10.1097/RLU.0000000000004313.
- [72] Scott M.L.J., Bromiley P.A., Thacker N.A., Hutchinson C.E., Jackson A.: A fast, model-independent method for cerebral cortical thickness estimation using MRI, *Medical Image Analysis*, vol. 13(2), pp. 269–285, 2009. doi: 10.1016/j.media.2008.10.006.
- [73] Shaw L.M., Korecka M., Clark C.M., Lee V.M.-Y., Trojanowski J.Q.: Biomarkers of neurodegeneration for diagnosis and monitoring therapeutics, *Nature Reviews Drug Discovery*, vol. 6(4), pp. 295–303, 2007. doi: 10.1038/nrd2176.
- [74] Simmons D.A., Mills B.D., Butler Iii R.R., Kuan J., McHugh T.L.M., Akers C., Zhou J., Syriani W., Grouban M., Zeineh M., Longo F.M.: Neuroimaging, Urinary, and Plasma Biomarkers of Treatment Response in Huntington’s Disease: Preclinical Evidence with the p75^{NTR} Ligand LM11A-31, *Neurotherapeutics*, vol. 18(2), pp. 1039–1063, 2021. doi: 10.1007/s13311-021-01023-8.
- [75] Singh N., Fletcher P.T., Preston J.S., King R.D., Marron J.S., Weiner M.W., Joshi S., Alzheimer’s Disease Neuroimaging Initiative (ADNI): Quantifying anatomical shape variations in neurological disorders, *Medical Image Analysis*, vol. 18(3), pp. 616–633, 2014. doi: 10.1016/j.media.2014.01.001.
- [76] Solberg O.K., Filkuková P., Frich J.C., Feragen K.J.B.: Age at Death and Causes of Death in Patients with Huntington Disease in Norway in 1986-2015, *Journal of Huntington’s Disease*, vol. 7(1), pp. 77–86, 2018. doi: 10.3233/JHD-170270.

- [77] Solmi M., Pigato G., Kane J.M., Correll C.U.: Treatment of tardive dyskinesia with VMAT-2 inhibitors: a systematic review and meta-analysis of randomized controlled trials, *Drug Design, Development and Therapy*, vol. 12, pp. 1215–1238, 2018. doi: 10.2147/DDDT.S133205.
- [78] Soni N., Ora M., Bathla G., Nagaraj C., Boles Ponto L.L., Graham M.M., Saini J., Menda Y.: Multiparametric magnetic resonance imaging and positron emission tomography findings in neurodegenerative diseases: Current status and future directions, *The Neuroradiology Journal*, vol. 34(4), pp. 263–288, 2021. doi: 10.1177/1971400921998968.
- [79] Srivastava A., Hanig J.P.: Quantitative neurotoxicology: Potential role of artificial intelligence/deep learning approach, *Journal of Applied Toxicology*, vol. 41(7), pp. 996–1006, 2021. doi: 10.1002/jat.4098.
- [80] Swaroop P., Sharma N.: An overview of various template matching methodologies in image processing, *International Journal of Computer Applications*, vol. 153(10), pp. 8–14, 2016. doi: 10.5120/ijca2016912165.
- [81] Tae W.S., Ham B.J., Pyun S.B., Kang S.H., Kim B.J.: Current clinical applications of diffusion-tensor imaging in neurological disorders, *Journal of Clinical Neurology*, vol. 14(2), pp. 129–140, 2018. doi: 10.3988/jcn.2018.14.2.129.
- [82] Tereshchenko A., Magnotta V., Epping E., Mathews K., Espe-Pfeifer P., Martin E., Dawson J., Duan W., Nopoulos P.: Brain structure in juvenile-onset Huntington disease, *Neurology*, vol. 92(17), pp. e1939–e1947, 2019. doi: 10.1212/WNL.0000000000007355.
- [83] Trovato B., Magri B., Castorina A., Maugeri G., D’Agata V., Musumeci G.: Effects of Exercise on Skeletal Muscle Pathophysiology in Huntington’s Disease, *Journal of Functional Morphology and Kinesiology*, vol. 7(2), 40, 2022. doi: 10.3390/jfknk7020040.
- [84] Umer F., Habib S.: Critical Analysis of Artificial Intelligence in Endodontics: A Scoping Review, *Journal of Endodontics*, vol. 148(2), pp. 152–160, 2022. doi: 10.1016/j.joen.2021.11.007.
- [85] Wilson H., De Micco R., Niccolini F., Politis M.: Molecular Imaging Markers to Track Huntington’s Disease Pathology, *Frontiers in Neurology*, vol. 8, 11, 2017. doi: 10.3389/fneur.2017.00011.
- [86] Wilson H., Dervenoulas G., Politis M.: Structural Magnetic Resonance Imaging in Huntington’s Disease, *International Review of Neurobiology*, vol. 142, pp. 335–380, 2018. doi: 10.1016/bs.irm.2018.09.006.
- [87] Wojcik G.M., Masiak J., Kawiak A., Kwasniewicz L., Schneider P., Postepski F., Gajos-Balinska A.: Analysis of Decision-Making Process Using Methods of Quantitative Electroencephalography and Machine Learning Tools, *Frontiers in Neuroinformatics*, vol. 13, 73, 2019. doi: 10.3389/fninf.2019.00073.

- [88] Yazdan S.A., Ahmad R., Iqbal N., Rizwan A., Khan A.N., Kim D.H.: An Efficient Multi-Scale Convolutional Neural Network Based Multi-Class Brain MRI Classification for SaMD, *Tomography*, vol. 8(4), pp. 1905–1927, 2022. doi: 10.3390/tomography8040161.
- [89] Young A.L., Oxtoby N.P., Ourselin S., Schott J.M., Alexander D.C.: A simulation system for biomarker evolution in neurodegenerative disease, *Medical Image Analysis*, vol. 26(1), pp. 47–56, 2015. doi: 10.1016/j.media.2015.07.004.
- [90] Yuan Q.: A Classroom Emotion Recognition Model Based on a Convolutional Neural Network Speech Emotion Algorithm, *PLoS One*, vol. 2022, 9563877, 2022. doi: 10.1155/2022/9563877.
- [91] Zhang L., Yue G.H.: Fractal dimension studies of the brain shape in aging and neurodegenerative diseases. In: A. Di Ieva (ed.), *The Fractal Geometry of the Brain*. Springer Series in Computational Neuroscience, pp. 213–232, 2016, Springer, New York, NY. doi: 10.1007/978-1-4939-3995-4_14.
- [92] Zhang S., Poon S.K., Vuong K., Sneddon A., Loy C.T.: A Deep Learning-Based Approach for Gait Analysis in Huntington Disease. In: L. Ohno-Machado, B. Séroussi (eds.), *MEDINFO 2019: Health and Wellbeing e-Networks for All*. Studies in Health Technology and Informatics, vol. 264, pp. 477–481, IOS Press, 2019. doi: 10.3233/SHTI190267.
- [93] Zhang Z., Jiang R., Zhang C., Williams B., Jiang Z., Li C.T., Chazot P., Pavese N., Bouridane A., Beghdadi A.: Robust Brain Age Estimation based on sMRI via Nonlinear Age-Adaptive Ensemble Learning, *IEEE Transactions on Neural Systems and Rehabilitation Engineering*, vol. 30, pp. 2146–2156, 2022. doi: 10.1109/TNSRE.2022.3190467.
- [94] Ziukelis E.T., Mak E., Dounavi M.E., Su L., O’Brien J.T.: Fractal dimension of the brain in neurodegenerative disease and dementia: A systematic review, *Ageing Research Reviews*, 101651, 2022. doi: 10.1016/j.arr.2022.101651.

Affiliations

Aleksandra Kawala-Sterniuk

Opole University of Technology, Faculty of Electrical Engineering, Automatic Control and Informatics, Proszkowska 76, 45-758 Opole, Poland,
“Vital Medic” Hospital, Department of Neurosurgery, Skłodowskiej-Curie 21,
46-200, Kluczbork, Poland, kawala84@gmail.com

Dariusz Mikolajewski

Kazimierz Wielki University in Bydgoszcz, Institute of Computer Science, Kopernika 1,
85-074 Bydgoszcz, Poland,
Neuropsychological Research Unit, 2nd Clinic of the Psychiatry and Psychiatric
Rehabilitation, Medical University in Lublin, Gluska 1, 20-439 Lublin, Poland,
darek.mikolajewski@wp.pl

Anna Bryniarska

Opole University of Technology, Faculty of Electrical Engineering, Automatic Control and Informatics, Proszkowska 76, 45-758 Opole, Poland, a.bryniarska@po.edu.pl

Maria Myslicka

Wroclaw Medical University, Faculty of Medicine, J. Mikulicza-Radeckiego 5,
50-345 Wroclaw, Poland, mariamyslicka38@gmail.com

Damian Czarnecki

Nicolaus Copernicus University in Torun – Collegium Medicum in Bydgoszcz,
Faculty of Health Sciences, Department of Preventive Nursing, Jagiellonska 15,
85-067 Bydgoszcz, Poland, czarneckidamian@cm.umk.pl

Anna Junkiert-Czarnecka

Nicolaus Copernicus University in Torun, Department of Clinical Genetics,
Faculty of Medicine, Collegium Medicum in Bydgoszcz, M. Curie-Sklodowskiej 9,
85-094 Bydgoszcz, Poland, ajczarnecka@cm.umk.pl

Adam Sudol

University of Opole, Faculty of Natural Sciences and Technology, Kardynala Kominka 6,
45-032 Opole, Poland, dasiek@dasiek.info

Emilia Mikolajewska

Nicolaus Copernicus University Collegium Medicum in Bydgoszcz,
Department of Physiotherapy, ul. Technikow 3, 85-801 Bydgoszcz, Poland,
emiliam@cm.umk.pl

Mateusz Pawlowski

“Vital Medic” Hospital, Department of Neurosurgery, Sklodowskiej-Curie 21,
46-200, Kluczbork, Poland,
St. Hedwig’s Regional Specialist Hospital, Department of Neurosurgery, ul. Wodociagowa 4,
45-221 Opole, Poland, mpawlowskimd@gmail.com

Anna Wlodarczyk

“Vital Medic” Hospital, Department of Neurosurgery, Sklodowskiej-Curie 21,
46-200, Kluczbork, Poland, wlodarczykana12@gmail.com

Piotr Walecki

Jagiellonian University in Krakow – Collegium Medicum, Department of Bioinformatics
and Telemedicine, Medyczna 7, 30-688 Krakow, Poland, piotr.walecki@gmail.com

Rafal Gasz

Opole University of Technology, Faculty of Electrical Engineering, Automatic Control
and Informatics, Proszkowska 76, 45-758 Opole, Poland, r.gasz@po.edu.pl

Witold Libionka

“Vital Medic” Hospital, Department of Neurosurgery, Sklodowskiej-Curie 21,
46-200, Kluczbork, Poland,
University Clinical Centre in Gdansk, Department of Neurosurgery, Debinki 7,
80-952 Gdansk, Poland, wlibionka@gmail.com

Bartosz Panczyszak

“Vital Medic” Hospital, Department of Neurosurgery, Sklodowskiej-Curie 21,
46-200 Kluczbork, Poland,
Jan Dlugosz University in Czestochowa, Faculty of Health Sciences, Waszyngtona 4/8,
42-217 Czestochowa, Poland, panczyszakkb@gmail.com

Mariusz Pelc

University of Opole, Institute of Computer Science, Oleska 48, 45-052 Opole, Poland,
University of Greenwich, School of Computing and Mathematical Sciences, Old Royal Naval
College, Park Row, SE10 9LS London, UK, m.pelc@gre.ac.uk

Jaroslaw Zygarlicki

Opole University of Technology, Faculty of Electrical Engineering, Automatic Control
and Informatics, Proszkowska 76, 45-758 Opole, Poland, j.zygarlicki@po.edu.pl

Henryk Racheniuk

Opole University of Technology, Faculty of Physical Education and Physiotherapy,
Proszkowska 76, 45-758 Opole, Poland, h.racheniuk@po.edu.pl

Katarzyna Bojkowska-Otrebska

Stobrawskie Medical Center in Kup, Clinical Department of Geriatrics, K. Miarki 14,
46-082 Kup, Poland,
University of Opole, Faculty of Medicine – Collegium Medicum, Oleska 48, 45-052 Opole,
Poland, kbojkowska@poczta.fm

Piotr Sterniuk

Opole University of Technology, Center for Technology Transfer, Proszkowska 76,
45-758 Opole, Poland, p.sterniuk@po.edu.pl

Edward Jacek Gorzelanczyk

Kazimierz Wielki University, Institute of Philosophy, Oginskiego 16, 85-092 Bydgoszcz, Poland
The Society for the Substitution Treatment of Addiction “Medically Assisted Recovery”,
Rzeźniackiego 1D, 85-791 Bydgoszcz, Poland, medsystem@medsystem.com.pl

Raffaele Ferri

Sleep Research Centre, Oasi Research Institute – IRCCS, Via Conte Ruggero 73,
94018 Troina, Italy, rferri@oasi.en.it

Received: 24.07.2023

Revised: 14.10.2023

Accepted: 14.10.2023